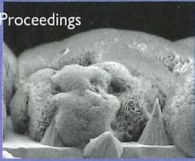

Indiana University School of Dentistry
Research Day

14th Annual Proceedings

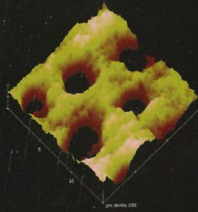
April 11-12, 2006

Presented by
IUSD and
Indiana Section,
American Association
for Dental Research



Indiana University School of Dentistry
RESEARCH DAY 2007


15th Annual Proceedings April 10-11



Presented by IUSD and Indiana Section, American Association for Dental Research

Indiana University School of Dentistry
RESEARCH DAY 2008

16th Annual Proceedings April 8-9



Presented by IUSD and Indiana Section, American Association for Dental Research

20TH ANNUAL INDIANA UNIVERSITY SCHOOL OF DENTISTRY RESEARCH DAY APRIL 16 2012

RESEARCH DAY


RESEARCH DAY
Indiana University School of Dentistry

Seventeenth Annual Proceedings




Presented in Association with Indiana Section, American Association for Dental Research

APRIL 23-24, 2009



INDIANA UNIVERSITY
SCHOOL OF DENTISTRY
RESEARCH DAY
Eighteenth Annual Proceedings
April 17, 2010
Presented in Association with
Indiana Section, American
Association for Dental Research



INDIANA UNIVERSITY
SCHOOL OF DENTISTRY
RESEARCH DAY

19th Annual Proceedings
April 11, 2011

PRESENTED IN ASSOCIATION WITH INDIANA SECTION, AMERICAN ASSOCIATION FOR DENTAL RESEARCH

GIOMER
TECHNOLOGY

BEAUTIFIL Flow Plus

FINALLY, an Injectable Hybrid Restorative
for All Indications

- Indicated in classes I, II, III, IV & V
- Physical properties rival hybrids
- Stackable & sculptable; stays put



BeautiBond

One Adhesive: Two Powerful Monomers

- Unique dual adhesive monomers deliver equal bond strength to enamel and dentin
- Only 5µm film thickness
- No HEMA

Now in
Bottles!



BEAUTIFIL II

A Nano-Hybrid Composite
with Fluoride Release & Recharge

- Sustained fluoride release and recharge
- Natural fluorescence
- 8 years of clinical success



Scan here for
testimonial and
technique videos or
visit www.shofu.com



Official Partner



Minimally Invasive
Cosmetic Dentistry

Smart Products for a Healthy Smile



Abrasives Diamonds Cements Whiteners Preventives Restoratives Ceramics



Shofu Dental Corporation • San Marcos, CA

Visit www.shofu.com or call 800.827.4638



Congratulations!

Delta Dental of Indiana would like to congratulate dentistry students on their Research Day presentations. Your hard work and dedication to dentistry is an inspiration to us all.

www.deltadentalin.com

**IUSD Research Day Proceedings
Volume 20, 2012**

| <i>Contents</i> | <i>Page</i> |
|--|-------------|
| Organizing Committee and Research Group Officers | 2 |
| Letter of Welcome INAADR | 3 |
| Letter of Welcome Dean Williams | 4 |
| Program | 5 |
| Introduction of Special Guest Speaker | 6 |
| Introduction of Keynote Speaker | 7 |
| Awards | 8 |
| Poster and Clinical Case Presentations | 9 |
| Exhibitors and Sponsors | 69 |
| Index to Presenters | 71 |

A special welcome to our guest presenters:

**The Ohio State University
College of Dentistry**

**University of Detroit Mercy
School of Dentistry**

**University of Louisville
School of Dentistry**

On the Cover: First through Nineteenth Research Day monograph covers – most designed by Mark Dirlam, Dental Illustrations, Indiana University School of Dentistry.

Cover design by Mark Dirlam. Research Day monograph prepared by Barbara A. Gushrowski

Research Day Organizing Committee

Sopanis D. Cho, Chair

Masatoshi Ando
William Babler
Chad Beckner
Marco Bottino
Angela Bruzzaniti
Tim Centers
Judith Chin
Jeffrey Dean
Mark Dirlam
Andréa Ferreira Zandoná
Dominique Galli
Ahmed Ghoneima
Richard Gregory
Karen S. Gregson
Barbara Gushrowski
Olga Isyutina
Sean Shih-Yao Liu
Marilyn Richards
Ali Sajadi
Adam Smith
Terry Wilson
Domenick Zero

Officers

Indiana Section

American Association for Dental Research

President: Sopanis D. Cho
Vice President: Angela Bruzzaniti
Secretary/Treasurer: Marco Bottino
Councilor: Sean Shih-Yao Liu

Officers

IUSD Student Research Group

President: Olga Isyutina
Secretary: Ali Sajadi
Faculty Adviser: Richard Gregory

Future Research Day Event:

April 15, 2013



INTERNATIONAL ASSOCIATION FOR DENTAL RESEARCH
AMERICAN ASSOCIATION FOR DENTAL RESEARCH

INDIANA SECTION

INDIANA UNIVERSITY SCHOOL OF DENTISTRY, 1121 WEST MICHIGAN STREET, INDIANAPOLIS, IN

April 16th, 2012

Dear Participants and Guests,

It is with the greatest pleasure that we welcome you to IUSD's Research Day. On behalf of the organizing committee, the Indiana Section of the American Association for Dental Research (IN-AADR) and the Student Research Group (SRG), we sincerely hope that you will enjoy our special program today to celebrate our 20th anniversary milestone.

Research Day is an annual event for the IUSD researchers, faculty, staff, and students to come together to present their research findings and clinical case studies. Since our first Research Day in 1993, this event continues to be a highlight of the academic year. IN-AADR encourages undergraduate, predoctoral, and graduate students to present their work at Research Day and fosters many opportunities for research collaborations. This year, we are delighted to have student representatives from dental schools at The Ohio State University, University of Detroit Mercy, and University of Louisville with us to present and participate in the inter-school research competition.

Following opening remarks by Dean John Williams and Dr. Jorge Jose, IU Vice President of Research, we will commemorate our 20th anniversary with presentations by two world renowned scientists in caries and craniofacial research.

Dr. George Stookey, IUSD professor emeritus who led in organizing our first Research Day in 1993, will talk about "Improved Health Through Research." Our keynote speaker, Dr. Martha J. Somerman, Director of the National Institute of Dental and Craniofacial Research (NIDCR), will present "NIDCR: Research Excellence, Advancing Oral Health."

We would like to offer a special word of thanks to our sponsors: Shofu, Delta Dental, and Johnson & Johnson, for their generous support. We also want to thank all the exhibitors for their participation. The success of this event depends on their continued support. We encourage you to visit with our exhibitors and acquaint yourself with the latest in dental products and services they have to offer.

We thank you all for participating in our 20th celebration. We are certain that you will enjoy this very special afternoon.

Sincerely,

Sopanis D. Cho, DDS, MSD
President, Indiana Section of the AADR

Olga Isyutina
SRG President



INDIANA UNIVERSITY

SCHOOL OF DENTISTRY

Office of the Dean
IUPUI

April 16, 2012

Indiana University School of Dentistry Colleagues,

Our School of Dentistry community is a contributor to the research agenda at Indiana University. I commend you – our faculty, students and staff – for 20 years of your commitment to supporting the vital activity of “scientific discovery” by hosting this signature event. Since 1993, Research Day has been an opportunity for the School of Dentistry to highlight the substantial collaborative research that is under way through programs sponsored by and affiliated with the school.

When we returned last year to the Research Day print monograph’s previous format of including all the researchers’ full abstracts, the key focus was to extend the educational experience of this day – simply put, to learn from the promising work of our colleagues. After the events have concluded and the posters have been taken down, the research continues. This book is a way to make sure we keep in mind the extraordinary variety of research in progress at our dental school, and the many ways this pursuit helps the practice of dentistry continually evolve.

Research provides the building blocks for improving human life and the world in which we live. Looking through this publication, you will find much creativity and innovation directed toward that purpose. Let’s take this day to congratulate our colleagues for their hard work and also offer them an encouraging word. Scientific discovery is a journey, not just a destination.

The careers of Dr. George Stookey and Dr. Martha Somerman, our featured speakers, attest to the innovation, hard work and joy found within research. I hope you will embrace their messages as well as attend the other events the Research Day planning committee has helped make possible. I sincerely thank the committee and the IN-AADR for their special efforts in recognition of this year’s 20th anniversary. I also thank our many sponsors who assist us in underwriting this event.

Thank you for being a part of this celebration and for the many ways you contribute to the Indiana University School of Dentistry’s missions of education, research, patient care and service. Our vision is to be “one of the best dental schools of the 21st century” – an active research program is one marker and measure of progress to achieve this vision.

Best wishes to all Research Day participants,

John N. Williams
Professor and Dean

Program
Campus Center 3rd and 4th Floor

Thursday, April 12

5:00 p.m. – 8:30 p.m. Poster Judging (Dental School)

Monday, April 16

8:00 a.m. – 11:00 a.m. Interschool Student Research Competition (CE 406)

12:00 p.m. Registration

12:30 p.m. Welcome Remarks
(CE 450A-B) **Dr. John N. Williams Jr.**
Dean, IUSD

12:35 p.m. Opening Remarks **Dr. Jorge José**
IU Vice President for
Research

12:40 p.m. Acknowledgment of Special
Sponsors and Announcements
of Faculty Awards **Dr. John N. Williams Jr.**

12:55 p.m. Introduction and Declaration
of George K. Stookey Day **Dr. John N. Williams Jr.**

1:00 p.m. Remarks from Special Guest **Dr. George K. Stookey**
IUSD Distinguished Professor
Emeritus

1:35 p.m. Keynote Address **Dr. Martha Somerman**
Director, NIDCR

2:15 p.m. Presentation of Awards **Dr. Sapanis D. Cho**
President
Indiana Section, AADR

2:30 p.m. – 4:30 p.m. Commercial Exhibitions (CE 450C)

Interschool Presentations (CE 406)
Research Presentations (CE 307, 405, 409)
2:30- 3:30 p.m.: Posters 1-63
3:30 p.m.-4:30 p.m.: Posters 64-89; Clinical Case Reports 1-32

4:30 p.m. Removal of Posters

Introducing the Plenary Speaker

George K. Stookey, BS, Ph.D.

A native of Indiana, Dr. Stookey is a Distinguished Professor Emeritus. He obtained his undergraduate and graduate education at Indiana University and was a member of the faculty of the Indiana University School of Dentistry from 1964 to 2001.

He has served as Director of the Oral Health Research Institute and as Acting Dean, Executive Associate Dean, and Associate Dean for Research. He retired from administrative responsibilities in 2001 to devote fulltime to research and acquired a start-up company, Therametric Technologies Inc., initially housed in the Indiana University Emerging Technologies Center in Indianapolis and now located in a new facility in Noblesville, Indiana.

His career has been devoted to research on the use of fluoride and other measures for the prevention and control of dental caries, strategies for the prevention of dental plaque, gingivitis and calculus as well as on the development of new technologies for the early detection of dental caries supported by NIDCR. He has 311 published reports in scientific journals, 56 U.S. and foreign patents and has contributed to 25 dental text or reference books. His memberships include International College of Dentists, American College of Dentists, International Association for Dental Research (IADR) and the European Organization for Caries Research.



Recent awards include the IADR Distinguished Scientist Award for Research in Dental Caries, the E.W.Borrow Memorial Award for Dental Caries Research from the IADR, and the ORCA-Zolnay Prize for Outstanding Contributions to Caries Research, European Organization for Caries Research (ORCA).

Presentation

IMPROVED HEALTH THROUGH RESEARCH

Numerous benefits have occurred as a result of dental research. These benefits include improved dental health and general health as a result of a decreased prevalence of dental caries, measures to prevent caries and periodontal disease, as well as improved restorative materials and treatment procedures. This brief presentation will review a few of the changes related to dental caries as a result of dental research including research at IUUSD.

Introducing the Keynote Speaker

Martha J. Somerman, DDS, PhD

Dr. Martha J. Somerman, who holds international repute as a periodontist, educator, researcher and administrator, has been the Director of the National Institute for Dental and Craniofacial Research since August 2011. Also, she is Chief of the Laboratory for Oral Connective Tissue Biology, National Institute of Arthritis and Musculoskeletal and Skin Diseases.

Dr. Somerman was the Dean of the University of Washington School of Dentistry and Professor in Periodontics, from 2002 to 2011 and Associate Dean for Research at the University of Michigan, Ann Arbor, from 2001-2002, as well as Professor in the Department of Periodontics/Prevention/Geriatrics. She chaired that department from 1995-2000 and was concurrently a professor in the Department of Pharmacology at the University of Michigan Medical School. From 1984 to 1990, she was an Assistant Professor and later an Associate Professor at the University of Maryland College of Dentistry in the departments of Periodontics and Pharmacology. In the early 1980s, she was a Staff Fellow at the National Institutes of Health/National Institute of Dental Research (NIH/NCDR).



Dr. Somerman earned her B.A. in biology from New York University and her D.D.S. degree from NYU in 1975. She then specialized in periodontology and pharmacology at the Eastman Dental Center and University in Rochester, NY, earning a certificate in periodontics and a Ph.D. in pharmacology.

Dr. Somerman's research focuses on defining the key regulators controlling development and maintenance and regeneration of tissues that form the dental-oral-craniofacial complex. In addition, she studies the appropriate cells, genes (factors), and scaffolds needed to rebuild periodontal structures lost through disease. Dr. Somerman has published more than 120 peer-reviewed articles and serves on several editorial boards, including those of the Journal of Dental Research and International Journal of Oral and Maxillofacial Implants. In the past, she has reviewed grants submitted to NIH/NIDCR and the NCRR, and has served on committees for the American Association for the Advancement of Science (AAAS) and the IADR/AADR (International/American Association for Dental Research) and American Dental Association.

Among Dr. Somerman's awards and honors are the William K. and Mary Anne Najjar Professorship at the University of Michigan, which she held from 1992 to 2002. She was named a diplomate of the American Board of Periodontology in 1990 and was president of AADR in 2001. Dr. Somerman has received the Geis Award from the American Academy of Periodontology (2003) and IADR's Distinguished Scientist Award for Research in Oral Biology (2005). In 2010, she received the IADR/Straumann Award in Regenerative Periodontal Medicine and in 2011, the Paul Goldhaber Award, Harvard School of Medicine. In addition, Dr. Somerman is a Fellow of AAAS, the International College of Dentists, and the American College of Dentists.

Presentation

NIDCR: RESEARCH EXCELLENCE, ADVANCING ORAL HEALTH

Recognizing Excellence

2012 List of Awards

Dental Hygiene

Elizabeth A. Hughes Dental Hygiene Case Report Award

Undergraduate Students

Johnson & Johnson Undergraduate Student Award

Predoctoral Dental Students

American Dental Association/Dentsply International Student Clinician Award

Cyril S. Carr Research Scholarship

INAADR Interschool Dental Student Research Award

INAADR Interschool Traveling Research Award

Indiana Dental Association Best Clinical Case Report Award

Johnson & Johnson IUSD Student Research Group Award

Procter & Gamble Award for Excellence in Preventive Oral Health Care

Graduate Dental Students

George K. Stookey Delta Dental Award for Innovation in Oral Care Research

Indiana Dental Association Best Clinical Case Report Award

Maynard K. Hine Award for Excellence in Dental Research

Shofu Dental Student Award

Postdoctoral Fellows

Shofu Dental Post-Doctoral Fellow Award

Staff

Delta Dental Excellence in Research Award to Staff Member

Faculty

Indiana University Trustees Teaching Awards

IU School of Dentistry Alumni Association Distinguished Faculty Award for Teaching

IU School of Dentistry Alumni Association Distinguished Faculty Award for Research

Poster Presentations

2:30 p.m. to 3:30 p.m.

P1 Effectiveness of Whitening Dentifrices on Enamel Extrinsic Stain. S. ALSHARA*,
F. LIPPERT, A.T. HARA (Indiana University School of Dentistry)

Whitening dentifrices utilize different approaches for stain removal and/or prevention, including the use of abrasive, oxidizing and chemical cleaning agents. The objectives of this in vitro study were: 1. to compare the whitening effect of commercial whitening and non-whitening dentifrices; 2. to verify the mechanism of action of whitening dentifrices by contrasting two experimental models: chemical (toothpaste exposure only) and chemo-mechanical (toothpaste exposure with tooth brushing abrasion). Two hundred fifty six bovine enamel specimens (10x10mm) were prepared and partially stained. They were assigned to 8 groups: 6 whitening dentifrices, 1 non-whitening reference dentifrice and deionized water (control); and further divided in 2 subgroups (n=16) according to the experimental models: chemical or chemo-mechanical. Specimens were daily exposed to dentifrice slurries 2x/day for 1min and brushed or not, according to each model. In between dentifrice treatments, specimens were exposed to the staining solution for 5h. This protocol was repeated for 5 consecutive days and enamel color changes (Delta E) were measured by spectrophotometry, after each day. The abrasivity of the toothpastes was determined using standard test (ISO 11609). Significantly higher Delta E values (whitening effect) were observed for all groups ($p < 0.05$), except control, when tested in the chemo-mechanical model. In this model, the whitening ability of the toothpastes was mainly determined by their abrasive levels. For the chemical model, no significant differences were observed among groups ($p > 0.05$). Whitening dentifrices can be effective preventing/removing enamel surface staining, when associated to tooth brushing abrasion. This seemed to be modulated mainly by the abrasive level of the tested toothpastes, with no action attributed to the chemical agents.

P2 Labeled versus actual concentration of bleaching agents in the United States. J.I. MATIS*,
B.A. MATIS, R. MILLARD (Indiana University School of Dentistry)

Objective: The purpose of this study was to determine if the actual concentrations of bleaching agents available in the United States were different than what is indicated on the label and if that difference was within the recommendations of the International Organization of Standardization (ISO). Methods: The method recommended by the United States Pharmacopeia (USP) for assaying peroxide, utilizing trituration of sodium thiosulfate, was used to determine the actual bleaching agent concentration of the products. Results: Thirty-five products were assayed. Of the bleaching agents tested, ninety-one percent were within 15% of the printed concentration and the other nine percent had a difference in the bleaching agent concentration that was greater than 15% but less than 30%. Bleaching gels were also assayed to determine their concentration on the month before expiration. On the month before the expiration, ninety-two percent of the bleaching products were assayed to have a loss that was greater than 30% of what was indicated on the label. The International Standard on Tooth Bleaching products requires at least 70% of the concentration that is indicated on the bleaching agent label. Conclusion: All products in the United States were within the established standard when the products were tested immediately upon delivery. Three of the 24 products in the United States had a concentration loss that was greater than 30% than the label indicated when they were tested on the month before the expiration date.

P3 Full-Contour Y-TZP Surface Roughness Effect on Wear of Hydroxyapatite. A. SABRAH*, P. LUANGRUANGRONG, N.B. COOK, A.T. HARA, M.C. BOTTINO (Indiana University School of Dentistry)

Full-contour yttrium-stabilized tetragonal zirconia polycrystal (Y-TZP) restorations have started to be advocated in clinical situations where occlusal/palatal space is limited or to withstand parafunctional activities. Objectives: To investigate the effects of different polishing techniques on the surface roughness of Y-TZP (Arden Dental, Inc) and on the wear behavior of synthetic hydroxyapatite (HA) utilized herein as a substitute for human enamel. Materials and methods: Thirty-two Y-TZP sliders ($\text{Ø}=2\text{mm}\times 1.5\text{mm}$ in height) were manufactured using CAD/CAM and embedded in acrylic resin using brass holders. Samples were then randomly allocated into four groups ($n=8$) according to the finishing/polishing procedure: G1-as-machined, G2-glazed, G3-diamond bur finishing (Brasseler, USA) and G4-G3+OptraFine[®] (Ivoclar-Vivadent). Thirty-two sintered HA disks ($\text{Ø}=11\text{mm}\times 2.9\text{mm}$ in height) were mounted in brass holders as previously described. Baseline surface roughness (R_a and R_q , in μm) were recorded using a non-contact profilometer (Proscan 2000). A two-body pin-on-disc wear test was performed for 25,000cycles at 1.2Hz. Vertical substance loss (μm) and volume loss (mm^3) of HA were measured (Proscan). Zirconia height loss was measured using a digital micrometer. One-way ANOVA was used for analysis. Results: Surface roughness measurements showed significant differences among the surface treatments with G1 ($R_a=0.84$, $R_q=1.13\mu\text{m}$) and G3 ($R_a=0.89$, $R_q=1.2\mu\text{m}$) being the roughest, and G2 ($R_a=0.42$, $R_q=0.63\mu\text{m}$) the smoothest. Glazed group showed the highest vertical loss ($35.39\mu\text{m}$) suggesting the wear of the glaze layer, while the polished group showed the least vertical loss ($6.61\mu\text{m}$). Antagonist volume loss and vertical height loss for groups (G1-G3) were similar, while polished group (1.3mm^3 , $14.7\mu\text{m}$) showed significant lower ($p=0.0001$) values. Conclusion: Although glazed full-contour zirconia provided an initially smooth surface, a significant increased antagonist wear compared to the polished surface was seen. Therefore, more studies need to be done before a more clinically relevant conclusion about the safety of placing full-contour zirconia restorations especially in Bruxer patient can be drawn. This research was partially supported by Ivoclar Vivadent Company, Buffalo, NY. And by Delta Dental Foundation Grant number 22-761-10.

P4 Nanofilled RMGI: Fracture Toughness, Surface Roughness and Gloss Testing. J. PALASUK*, J.A. PLATT, W. BROWNING, S. CHO (Indiana University School of Dentistry)

Resin modified glass ionomer (RMGI) utilizing nanofiller technology, KetacTM Nano (KN), was introduced. The manufacturer claims that the smaller particles enhance the physical properties of this material including fracture toughness (K_{IC}), surface roughness and gloss. Objective: The purpose of this study was to compare the K_{IC} , surface roughness (R_a , R_q) and gloss of KN to those of two GIs, a RMGI, a compomer and a resin composite (RC). Materials and Methods: Six restorative materials were compared: 1) Ketac Nano (KN); 2) Esthet-X (EX); 3) Geristore (GS); 4) Photac Fil (PF); 5) Ketac Fil Plus (KF), and Fuji IX (F9). A total of 144 specimens with the dimensions of $5 \times 25 \times 2.5$ mm for K_{IC} testing ($n=12$), and dimension of $5 \times 20 \times 2$ mm for gloss and surface roughness testing ($n=12$) were fabricated. After completed polymerization, specimens were polished using silicon carbide paper grits 400, 600, 800 and 1,200, consecutively. After 24 hours, specimens were loaded in a three-point bending with a crosshead speed 0.2 mm/min. Gloss was measured using Gloss Checker. Surface roughness (R_a , R_q) was measured using Stylus Profilometer. Data were analyzed with One-way ANOVA. Results: KN had higher K_{IC} than the other RMGI (PF) and GI (KF, F9) ($p<0.05$) but lower than compomer (GS) and resin composite (EX) ($p<0.05$). Moreover, KN showed higher gloss value and lower surface roughness than all materials being tested ($p<0.05$) except EX. Conclusion: KN had higher fracture toughness values than the other RMGI and GI tested; higher gloss values than all materials except the RC; and lower surface roughness values than all materials except the RC.

P5 ***BENS, Bone and Connective Tissue Regeneration Agent for Osteoporosis.*** N. LABBAN^{1, 2*}, M. AREF¹, D. BROWN¹, M. ALLEN³, A. BRUZZANITI¹, S. LIU¹, L. J. WINDSOR¹ (¹Indiana University School of Dentistry; ²King Saud University College of Dentistry; ³Indiana University School of Medicine)

Each year, more than 1.5 million osteoporosis related fractures occur. Significant morbidity, mortality and health care costs are associated with these fractures. Some success in increasing bone mass and reducing fracture risk has been seen with treatments with the anabolic agent parathyroid hormone (PTH), but clinical use is limited to two years due to safety concerns and its use is contraindicated in some individuals. Traditional medicines have been used for thousands of years to treat various ailments, including bone healing. In this pilot study, we used a rat model of post-menopausal osteoporosis to investigate the skeletal effects of a traditional nutritional supplement, which we have tentatively named *BENS* (*Bone Enhancing Nutritional Supplement*; US patent pending). Six months old female Sprague-Dawley rats that had received sham surgeries or ovariectomy (OVX) were used. Rats were randomized into six groups and 6 rats per group were used. Four weeks after the initial surgery, rats received daily intraperitoneal injections for 4 weeks as follows; saline-treated sham group, saline-treated OVX group, PTH-treated OVX group (10 µg/kg/day), 3 mg/kg/day *BENS*-treated OVX group, and 30 mg/kg/day *BENS*-treated OVX group. Six rats were used as baseline OVX controls and were euthanized at the start of the treatment period. Dynamic histomorphometric measures, indicating the amount of active bone formation, were obtained for both cortical and trabecular bone. Bone formation rates (BFR) on the cortical periosteal bone surface of the midshaft tibia were as follows; sham (383.2±193.7), OVX (223.9±74.2), PTH (308.8±112.3), 3mg/kg *BENS* (304.9±117.2) and 30mg/kg *BENS* (370.9±161.3), respectively. The BFR rates for trabecular surfaces were; sham (82.2±21.1), OVX (113±46.1), PTH (212.1±86.6), 3mg/kg *BENS* (157±59.4) and 30mg/kg *BENS* (165±62.4). There were no significant differences between groups by ANOVA comparison, most likely due to the small sample size in this first cohort of animals. Trends in the results from *BENS*-treated animals suggest the drug may possess anabolic properties and a second cohort of animals is currently being used to increase the group sizes. Supported by CTSI grant No. 2276302.

P6 ***Progression of Caries Lesions over 48 months Using ICDAS According to Activity Status at Baseline.*** A. FERREIRA ZANDONÁ* (Indiana University School of Dentistry)

Objective: Compare dental caries progression in children enrolled on a 4 year longitudinal study in rural schools in the Commonwealth of Puerto Rico by tooth surface over a 48 month period using the International Caries Detection and Assessment System (ICDAS) and an activity assessment. Methods: 331 children provided informed consent and were examined with ICDAS at baseline (BL) and 4 month intervals for 48 months. Lesions were assessed as active/inactive using subjective criteria based on surface characteristics and plaque stagnation status. Enrolled children (49% female, 51% male) ranged from 5-13 yrs old (mean 9.27) and were mostly Hispanic (90%). Results: Focusing on permanent tooth surfaces without fillings at BL and scored ICDAS 0-3, progression of lesions varied according to severity scores and activity assessment. Progression was defined as worsening ICDAS score (ICDAS 0-3 to ICDAS 4- 6) and/or placement of a filling. Only 3% of surfaces scored as sound at BL progressed to cavitation, while 25% of the lesions scored as ICDAS 1 progressed to cavitation but they were just as likely to progress if they were considered active (22%) or not (27%), while almost 40% of lesions scored as ICDAS 2 to cavitation and they were twice as likely to progress if they were considered active (41% versus 21%). Over 80% of lesions scored ICDAS score 3 progressed to cavitation, and if considered active the likelihood of progression was even stronger (84% PPV versus 25% PPV). Conclusions: Characterization of lesion severity with ICDAS can be a strong predictor of lesion progression to cavitation. Supported by NIH/NIDCR RO1DE017890-05

P7 Carious Lesion Progression over 48 months by Quantitative Light-Induced Fluorescence. G.GOMEZ^{1*}, M. ANDO¹, G. ECKERT², A. FERREIRA ZANDONÁ¹ (¹Indiana University School of Dentistry; ²Indiana University School of Medicine)

The aim of this study was to determine if caries lesions that progress to cavitation as determined by the International Caries Detection and Assessment System (ICDAS) have a different fluorescent profile than lesions that do not progress. Children (569) aged 5 to 13 years from a rural school district in the commonwealth of Puerto Rico were consented and enrolled at baseline. Buccal, lingual and occlusal surfaces of erupted permanent molars were assessed by ICDAS and Quantitative Light-Induced every 4 months over a 48-month period. QLF images of 368 surfaces that had an ICDAS score of 0/1/2/3/4 at baseline and progressed to ICDAS scores 5,6 and 377 surfaces that had an ICDAS score of 0/1/2/3/4 at baseline but had no progression during the 48-month were analyzed independently by calibrated examiners. QLF parameters lesion area (Δ Area in mm²), lesion depth defined as fluorescence loss (Δ F) and lesion volume defined as fluorescence loss over area (Δ Q) were obtained. Mixed-model factorial Analysis of Variance (ANOVA) was employed to compare the means and slopes (change over time) between surfaces with progression and surfaces with no progression. There were no statistically significant differences between lesions that progressed versus those that did not progress in relation to area, overall surfaces or buccal, lingual and occlusal surfaces. However, fluorescence loss (Δ F) was greater in lesions that progressed overall ($p < 0.0001$) and in buccal, lingual and occlusal surfaces ($p < 0.0001$) versus those surfaces with not progression. Δ Q was significantly greater for lesions that progressed for overall ($p = 0.0005$), lingual ($p = 0.0099$) and occlusal ($p = 0.0250$) surfaces versus those that did not progress. Except for area of buccal surfaces, lesions that progressed experienced faster changes than lesions that did not progress (significant slope difference) across all other QLF parameters and surfaces ($p < 0.03$). Conclusion: Based on the analyses of these sample of images, QLF parameters, specially Δ F can differentiate between lesions that progress and those that do not progress. Supported by NIH/NIDCR RO1DE017890-05.

P8 Fluoride Content of Commercially Available Infant Foods. E.A. MARTINEZ-MIER* (Indiana University School of Dentistry)

Excessive fluoride (F) consumption during the first two years is associated with increased risk for enamel fluorosis. Estimates of fluoride intake from various sources may aid in the determination of children's risk for developing enamel fluorosis. The current study aimed at assessing the fluoride content of commercially available infant foods consumed by children 12 months old and younger. Five types of infant foods (fruits, vegetables, chicken dinners, turkey dinners, and non-chicken dinners) intended for children 1 year old and younger, from three brands, were sampled. Samples were homogenized and frozen until time of analysis. Fluoride analysis was conducted blindly, in triplicate, using a modification of the HMDS microdiffusion method. Mean and standard deviations were calculated for each food by brand and specific type. Variance components ANOVAs were performed to estimate the variability between production lots. ANOVAs were also used to compare the fluoride concentrations among infant food types. 360 samples were tested. Fruits had a mean 0.059 ± 0.018 μ g F/g; vegetables had 0.139 ± 0.039 μ g F/g; non-chicken dinners had 0.164 ± 0.065 μ g F/g; turkey dinners had 0.315 ± 0.242 μ g F/g; and chicken dinners had 0.578 ± 0.257 μ g F/g. A chicken product had the highest fluoride concentration among all products (4.13 μ g F/g), while a turkey product had the second highest concentration (1.25 μ g F/g). For each brand, chicken based products had statistically significant higher mean F concentration. Products using mechanically separated chicken and turkey had the highest fluoride concentrations. All products not containing chicken or turkey (fruits, vegetables and non-chicken dinners) contained < 0.54 μ g F/g. Variability between production lots was not statistically significantly different. All foods tested had detectable amounts of fluoride; therefore we conclude that commercially available infant foods should be taken into account when calculating total daily fluoride intake.

P9 Evaluation of a Caries Risk Assessment Program: Analysis of Focus Groups with Students and Faculty. O. ISYUTINA*, G. MAUPOMÉ (Indiana University School of Dentistry)

Caries treatment should include lesion removal and tooth restoration as well as amelioration of risk factors. Our Caries Risk Assessment (CRA) program gauges the risk of new lesions and leads to a management plan (CRM). Past program evaluations showcased positive features but also demonstrated uneven compliance. The present study has Objectives 1) to characterize emotions and concepts that faculty and students use while undertaking CRA/CRM; 2) to identify intervention points to make the program more user-friendly; and 3) to offer practical strategies to improve program operation. Our Method relied on 5 focus groups, including 25 students and 15 faculty (separate). Transcripts of discussions were qualitatively analyzed for Emotions (Plutchik's model); and for Concepts, inductively identified from text to create a classification. Results showed that few basic Emotions were identified in the discourses of students and faculty (N=554). *Admiration* and *Loathing* had low frequencies; *Vigilance* was higher. A few positive Emotions used to discuss CRA/CRM experiences were *Interest*, *Anticipation*, *Optimism*, as well as *Trust*, *Acceptance*, *Surprise*, and *Vigilance*. Most Emotions were mildly negative. Concepts (N=538) were assembled in 8 groups. Students and faculty supported the CRA/CRM notion as *Useful* and *Important*. Faculty stressed its being *Desirable Because of Legal/Ethical Implications*. Its *Role in Dental Care* was often linked to *More Appropriate Management*; helped patients *Transition from Higher Risk to Lower*; led to *Improved Outcomes*, and made *Patients More Engaged*. Students emphasized the opportunity to *Motivate/Educate Patients*. Students found the CRA/CRM form to be either *Well-Structured* or *Frustrating/Tedious*. Some students and faculty stated the program was *Poor Use of Time*, *Useless*, or *Undermining Its Importance and Compliance by Students and/or Faculty*. Faculty felt the form could be improved by having *Pre-Filled Segments*, and by *Having Applicable Outcomes*. Making the form *Shorter* and/or *Easier* was often stated – including restricting the *Long Form Only to Pre-Clinical Students*, or *Reserved for Complex Cases*. The main shortcomings were *Long Wait for Faculty to Review Cases* and *Poor Support by Clinical Faculty* (students). Faculty pointed *Lack of Training to Use the Program*, and of *Calibration*; above all, *Stress for Time* and *Competing Demands between Program and Restorative Care*. Conclusion. Clearer messages, simpler forms and systems, and better-tailored foci of the program for different students and faculty sub-groups may dispel misconceptions. It is crucial that form and program are seen as being relevant to clinical thinking; useful and simple; and leading to tangible outcomes for patients and clinicians.

P10 Non-Destructive Analysis of Artificial Caries Lesions in Human Enamel. E.K. KOHARA^{1*}, H. ZHANG², R. ARTHUR¹, G. ECKERT³, M. ANDO¹ (¹Indiana University School of Dentistry; ²Pervasive Technology Institute, Indiana University; ³Indiana University School of Medicine)

Objective: To evaluate the ability of three non-destructive techniques for assessing enamel demineralization with microbial caries formation model. Methods: Twenty-one 3x3x2mm human enamel slabs were used in this study. They were equally divided into three groups. Prior to demineralization, all specimens were measured with the following techniques: Quantitative Light-induced Fluorescence after 10-seconds dehydration (QLF; Fluorescence change [%]), surface profilometry (SP; Ra [μm]) and microfocus computed tomography (μCT , volume [μm^3]) constructed from pixels with grayscale less than 87). Then all specimens were covered with nail varnish except a 2x1mm rectangle of exposed enamel to bacterial environment. They were incubated in a microbial model for caries formation with 5 species of oral bacteria (*Actinomyces naeslundii*, *Lactobacillus casei*, *Streptococcus mutans*, *Streptococcus salivarius* and *Streptococcus sanguinis*), 3% sucrose in Tryptic Soy Broth and 0.75ppm fluoride in artificial saliva for three, six and nine days. After termination of microbial model, QLF, SP and μCT measurements were performed. Group comparisons were made using Wilcoxon Rank Sum tests. Results: QLF, SP and μCT results are presented in the table below. QLF values increased as incubation time

increased. 6 days values of SP and μ CT were slightly higher than 3 and 9 days. Statistical differences ($p < 0.05$) were found only on QLF (between 3 and 9 days).

| Period | QLF Fluorescence change after 10s dehydration (%) | SP Ra (μ m) Sound | SP Ra (μ m) Demin | μ CT <87% grayscale volume (μ m ³) Sound | μ CT <87% grayscale volume (μ m ³) Demin |
|--------|---|------------------------------|------------------------------|--|--|
| 3 Days | 0.39 \pm 0.16 * ^a | 0.26 \pm 0.04 | 1.43 \pm 1.01 | 9,675 \pm 6,100 | 243,324 \pm 136,769 |
| 6 Days | 0.62 \pm 0.28 ^{ab} | 0.41 \pm 0.15 | 1.48 \pm 1.19 | 74,717 \pm 135,803 | 252,016 \pm 99,218 |
| 9 Days | 0.74 \pm 0.18 * ^b | 0.63 \pm 0.30 | 1.30 \pm 0.92 | 6,699 \pm 5,532 | 136,962 \pm 92,208 |

Conclusion: Based on the results of this study, QLF and SP presented a potential to evaluate enamel demineralization. However, μ CT did not show the same potential at this time. Support: NIH/NIDCR R21 DE018390-01A2.

P11 Sucrose/Fluoride Effects on Enamel-Caries-Initiation Produced by a Microbial Model. R.A. ARTHUR^{1*}, E.K. KOHARA¹, A. WAEISS¹, G. ECKERT², D. ZERO¹, M. ANDO¹ (¹Indiana University School of Dentistry; ²Indiana University School of Medicine).

Dental caries is a multifactorial disease related to frequent intake of fermentable carbohydrates and to microbial biofilm growth on the surface of the teeth. Sucrose is considering the most cariogenic dietary carbohydrate since the biofilm formed on its presence has an altered tridimensional structure affecting the diffusion properties of the biofilm matrix and increasing its cariogenicity. In this context, fluoride plays a key-role in the prevention and control of this disease. Therefore, the aim of this study was to evaluate the effects of sucrose and fluoride concentrations on enamel demineralization produced by a multispecies microbial model. Biofilms formed by *Actinomyces naeslundii*, *Lactobacillus casei*, *Streptococcus mutans*, *Streptococcus salivarius* and *Streptococcus sanguinis* were grown on the surface of twenty-eight human enamel specimens (3 \times 3 \times 2mm) during 5 days. During this period of time, biofilms were exposed to artificial saliva enriched with fluoride (0.50 or 0.75 ppmF; 22.5 h/day) and to broth enriched with sucrose (3 or 5%, 30 min; 3x/day) according to the following design: 0.50 ppmF and 3% sucrose (G1), 0.50 ppmF and 5% sucrose (G2), 0.75 ppmF and 3% sucrose (G3) or 0.75 ppmF and 5% sucrose (G4). Counts of viable cells were on biofilms (n=7/group) were assessed after 5 days of biofilm formation. Enamel specimens (n=7/group) were sectioned through the center and 100 μ m slices were analyzed regarding lesion depth (LD; μ m) and integrated mineral loss (IML; vol% \times μ m) via Transversal Microradiography (TMR). The results were analyzed by 2-way ANOVA. No differences were found in counts of total cells among different groups. Counts of *L. casei* and *S. salivarius* were in the range of 10⁷ CFU/mL; counts of the other species were below the detection limit. TMR analysis showed that specimens exposed to 0.50 ppmF had deeper lesions (LD: G1=71.3 \pm 3.8; G2=70.1 \pm 11.4) and higher IML (G1=2251.6 \pm 340.9; G2=2483.9 \pm 310.6) than those exposed to 0.75 ppmF (LD: G3=48.6 \pm 10.6 and G4=48.7 \pm 2.5; IML: G3=1501.4 \pm 279.0 and G4=1544.0 \pm 105.2) ($p < 0.005$). No significant effect of sucrose concentrations was found in respect to LD and IML ($p > 0.05$). Under the conditions of this study, although distinct sucrose concentrations did not affect enamel demineralization, our results suggest that the severity of enamel demineralization was reduced by the presence of the highest fluoride concentration. Support: NIH/NIDCR R21 DE018390-01A2.

P12 Kalirin Decreases Bone Mass Through Effects on Osteoclasts and Osteoblasts. S.HUANG^{1*}, P. ELENISTE¹, P. LEBLANC², D. BROWN², M. ALLEN², A. BRUZZANITI^{1,2}
(¹Indiana University School of Dentistry; ²Indiana University School of Medicine)

Bone homeostasis is maintained by the balance between osteoclasts which degrade bone and osteoblasts, which form new bone. When the activity of either of these cells is dysregulated, bone loss can ensue, leading to osteoporosis, a disease characterized by low bone mass and an increase in bone fragility and risk of fracture. The activity of osteoclasts and osteoblasts is regulated by local and systemic factors. Kalirin is a novel GTP-exchange factor protein that plays a role in signaling pathways leading to cytoskeletal remodeling and dendritic spine formation in neurons, but its function in other cells is unknown. Western blotting and PCR confirmed that Kalirin is expressed in osteoclasts and osteoblasts, suggesting its potential role in regulating bone cell function and bone mass. We used micro-CT to examine the bone phenotype of 14 week old female mice. Kal-KO mice (global knockout) exhibited a 40% lower trabecular bone volume in the distal femur compared to wild-type (WT) mice (n=9/group, p<0.05). We next quantified osteoclasts in histological sections by counting multinucleated cells expressing tartrate-resistant acid phosphatase (TRAP), a marker of mature osteoclasts. We found 48% higher osteoclast surface/bone surface in trabecular bone of Kal-KO mice, compared to WT mice (n=6/group, p<0.05). Osteoclast differentiation is controlled by osteoblasts, which secrete receptor activator of NF- κ B ligand (RANKL), macrophage colony stimulating factor (MCSF) and osteoprotegerin (OPG), a decoy receptor for RANKL. We examined if Kalirin could regulate osteoclast differentiation *in vitro*. Osteoclasts were generated from the bone marrow of WT or Kal-KO mice by incubation with RANKL and MCSF for 7 days, and TRAP⁺ multinucleated cells were counted. Consistent with our *in vivo* studies, osteoclast number was significantly higher in cultures from Kal-KO mice, compared to WT mice. We next examined if Kalirin altered the ratio of RANKL and OPG secreted by osteoblasts. Osteoblasts were generated from the calvaria of 2 day old neonates and the level of RANKL and OPG in conditioned media was quantified by ELISA. Consistent with increased osteoclast differentiation, we found a higher RANKL/OPG ratio in conditioned media from Kal-KO osteoblasts, compared to WT cells. Our results demonstrate that Kalirin decreases trabecular bone mass through effects on both osteoclasts and osteoblasts.

P13 Predictors of Difficulty on the National Board Dental Exam. M. ELY*, W. SENOUR, K.T. STEWART (Indiana University School of Dentistry)

Background: Becoming a certified dental professional requires the completion of a rigorous educational process that consists of a minimum of four years of clinical, didactic, and research demands. One of the major benchmarks in this process is the successful completion of the National Board Dental Exam (NBDE) part I and II. Each year roughly 100 students matriculate into the Indiana University School of Dentistry (IUSD) dental program. Of those, approximately 3-5% of each cohort is unsuccessful at becoming a certified dentist because of an inability to successfully pass the NBDE. Objective: The aim of this study was to assess demographic and academic factors that could predict or explain poor performance on part I of the NBDE. The overall goal is to use the results obtained through this study to identify students who are at risk of performing poorly on these high stakes exams and proactively provide support to these individuals. Materials and Methods: The data used in this study was obtained from the academic records of IUSD dental graduates between the years of 2003-2008, (n = 537). After obtaining IRB approval, approximately 30 demographic/academic items were extracted from each student's academic record. A mixed-model analysis of variance (ANOVA) and correlation coefficients were used to assess the relationships of each predictor with the NBDE part I scores. A stepwise linear regression was used to create a prediction model. A significance level of p < 0.05 was established for the study. Results: The prediction model revealed that the following predictors were most significant towards explaining NBDE part I performance: D1 GPA, DAT total science scores, anatomic science scores from the D2 mock board

exams, D2 GPA, gender, DAT reading comprehension scores, microbiology/ physiology scores from the D1 mock board exams, and the total number of science credit hours taken prior to dental school. These predictors explained 62.1% of variability associated with the student's results on the part I NBDE. The most significant of these factors were D1 GPA and DAT total science scores, which explained 51.4% of the students' performance. Conclusion: The results suggest that there are eight key factors that can be used to help identify dental students who may be most at risk for not passing part I of the NBDE.

P14 Strengthening Dental Students' Anatomical Foundational Knowledge for Local Oral Anesthesia: Development and Implementation of an Instructional Multimedia Program.
B. WERNER*, J. BRUECKNER-COLLINS, R. ACLAND (University of Louisville School of Dentistry)

Objectives: Many dental students feel insufficiently prepared for administering their first injection of local oral anesthesia in patients and cite anatomical knowledge as an area in which they feel underprepared entering their clinical training. This educational study focused on remedying this issue through the design and development of an instructional video addressing the clinical anatomy of the inferior alveolar nerve (IAN) block, using fresh tissue cadaveric material. Methods: The tutorial was designed and storyboarded, with the goal of reviewing pertinent anatomy of the infratemporal fossa and relating its key features to administration of a successful IAN block. Anatomical dissections were video-documented in sagittally sectioned cadaver heads, demonstrating IAN anatomy from various views. The video clips were assembled into an instructional tutorial using Adobe After Effects CS 5.5. Video footage was collected from lateral, superior and medial dissection approaches. Results: Student users are most familiar with the lateral dissection and thus, the program begins with this perspective. The masseter was resected to demonstrate the mandibular ramus, which was removed to show the contents of the infratemporal fossa, including the IAN. The next dissection was conducted from a superior view, in which a block of bone overlying the IAN was mobilized by cutting sphenoid from superior orbital fissure back to the petrous ridge, lateral to foramen ovale. This allows for an examination of the IAN's course approaching mandibular foramen. The final dissection view was from a medial perspective so that the student user could trace the path of needle during the IAN injection. The buccinator, superior pharyngeal constrictor and medial pterygoid muscles were removed to show the IAN entering mandibular foramen just behind the lingula. Conclusion: This instructional video provides a clinical oriented review of the IAN and its nerve block for dental students at all levels of training.

P15 A Novel Antibacterial Resin Composite Containing Quaternary Ammonium Salts.
L. HOWARD^{1*}, Y. WENG¹, X. GUO¹, V.J. CHONG¹, R.L. GREGORY², D. XIE¹, (¹Indiana University-Purdue University Indianapolis; ²Indiana University School of Dentistry)

Objectives: The objective of this study was to synthesize new quaternary ammonium bromide (QAB)-containing oligomers, incorporate them to dental resin composites, and evaluate the effects of these new oligomers on the mechanical strength and antibacterial activity of the formed composites. Methods: The novel quaternary ammonium bromide (QAB)-containing oligomers were synthesized and applied for developing an antibacterial resin composite. Compressive strength (CS) and *S. mutans* (an oral bacteria strain) viability were used to evaluate the mechanical strength and antibacterial activity of the formed composites. Results: All the QAB-modified resin composites showed significant antibacterial activity and mechanical strength reduction. Increasing chain length and loading significantly enhanced the antibacterial activity but dramatically reduced the CS. The 30-day aging study showed that the incorporation of the QAB accelerated the degradation of the composite, suggesting that the QAB may not be well suitable for development of antibacterial dental resin composites or at least the QAB loading should be well controlled, unlike its use in dental glass-ionomer cements. Conclusion: The work in this

study is beneficial and valuable to those who are interested in studying antibacterial dental resin composites. This work was sponsored by NIH challenge grant (RC1) DE020614.

P16 Preparation and Evaluation of an Antibacterial Dental Cement. V.J. CHONG^{1*}, Y. WENG¹, X. GUO¹, L. HOWARD¹, R.L. GREGORY², D. XIE¹ (¹Indiana University-Purdue University Indianapolis; ²Indiana University School of Dentistry)

Objectives: The objective of this study was to develop an antibacterial cement and evaluate its mechanical strength and antibacterial activity. Methods: The newly synthesized quaternary ammonium bromide (QAB)-containing antibacterial polymers were initially evaluated using a MIC/MBC test and then incorporated into Fuji II LC cement. Compressive strength (CS) and viabilities of oral cavity-producing bacteria *S. mutans* and lactobacillus were used to evaluate the mechanical strength and antibacterial activity of the cement, respectively. Flexural (FS) and diametral tensile strengths (DTS) were tested as well. The specimens were conditioned in distilled water at 37°C for 24 h prior to testing. Results: The cement showed a significant antibacterial activity to both oral bacteria, accompanying with an initial CS reduction. The effects of chain length and loading of the QAB were significant. Conclusion: It was found that the antibacterial effect of the substitute chain lengths from free QAB seem more significant in water than those from their polymers after integrating to the cement. It was also found that the antibacterial activity against lactobacillus was higher than that against *S. mutans*. This work was sponsored by NIH challenge grant (RC1) DE020614.

P17 Evaluation of Microtensile Bond Strength and Microleakage of a One-step Self-etch Adhesive. A. ALZAIN^{1*}, G. ECKERT² and J.A. PLATT¹ (¹Indiana University School of Dentistry; ²Indiana University School of Medicine)

Selective phosphoric acid etching of enamel when using a self-etch adhesive may enhance enamel bonding, but may adversely affect bonding to dentin. The objective was to evaluate the microtensile dentin bond strength (μ -TBS) and microleakage of a one-step HEMA-free self-etch adhesive “designed for selective etching” (G-aenial Bond-GB) compared to 2-step self-etch (Clearfil SE-SE) and 3-step etch-&-rinse (OptiBond FL-OB) adhesives using two different bonding techniques; with and without additional etching. For μ -TBS testing, human molars were divided randomly into 5 groups (n=15). In groups GB, SE, and OB, each adhesive was used on dentin following manufacturer’s instructions. In GB+ and SE+, etching with phosphoric acid prior to applying the adhesive was performed. Beams were stored in artificial saliva at 37°C, where half of the beams were tested after 48h and half were tested after thermocycling for 2500 cycles and aging for 40 days. Testing was done using a universal testing machine with crosshead speed of 1 mm/min. The fractured interfaces were analyzed using light microscopy. Data will be analyzed using Weibull, GEE and regression methodologies ($\alpha=0.05$) after test completion. For microleakage evaluation, human molars were divided randomly into the same 5 groups as μ -TBS test (n=11). Class V was prepared on the buccal and lingual surfaces of each tooth. Teeth were then thermocycled for 2500 cycles, aged for 4 weeks, soaked in 1% methylene blue for 24 hours and sectioned. The dye penetration was evaluated using light microscopy (10x) and scored using an ordinal scale from 0-3. Wilcoxon Rank Sum tests were used to compare the differences in microleakage scores ($\alpha=0.05$). Statistical analysis for μ -TBS test is yet to be performed. According to the mean bond strength for μ -TBS test, GB bond strength decreased after 40 days. For the microleakage test, coronal and gingival surfaces were significant for SE, SE+ and OB. Materials were supplied by GC America and Ultradent.

P18 The Effect of Nano-Filled Resin Coating on Fluoride Release in a New Conventional Glass Ionomer Cement. L. AL DEHAILAN^{1*}, G. ECKERT² and J.A. PLATT¹ (¹Indiana University School of Dentistry; ²Indiana University School of Medicine)

The objective of this study was to evaluate fluoride release amounts and patterns from high strength conventional GIC (EQUIA™) and investigate whether the application of nano-filled resin-based coating with different thicknesses has any effect on fluoride release from this new material. A total of 120 disc shaped specimens (10x 2 mm) of EQUIA™ were fabricated according to manufacturer's instructions. Samples were subsequently divided into three groups: no resin coating; coated with nano-filled resin-based coat; coated with nano-filled resin-based coat then subjected to abrasion using a mechanical tooth brushing machine. Each specimen was soaked individually into a polyethylene container with 20 ml of distilled water and stored at 37°C. Samples from each group were soaked for four time points; 1 day, 7 days, 14 days and 21 days. Fluoride content was then measured using a fluoride-specific ion electrode (Model 9609BNWP, Orion Research, Boston MA, USA). The effects of time and coating on fluoride release were analyzed using two-way analysis of variance (ANOVA), with multiple comparisons performed using the Sidak method at an overall 5% significance level. The distribution of the fluoride release measurements was examined and a natural logarithm transformation of the data was necessary to satisfy the ANOVA assumptions. The time-by-coating interaction was significant ($p < 0.0001$). We can conclude that fluoride level significantly increased with time for non-coated and coated then abraded samples only. Application of resin coat significantly reduced fluoride release. Also, subjecting coated samples to tooth brush abrasion increased the fluoride release when compared to coated specimens but was still significantly less than uncoated samples. EQUIA™ was provided by GC America.

P19 Evaluation of the Microhardness and Antibacterial Properties of Triclosan-incorporated Acrylic and Composite Resin. K. SO*, K.S. GREGSON, R.L. GREGORY (Indiana University School of Dentistry)

This study investigated the microhardness and antibacterial properties of composite and acrylic resins modified by the addition of Triclosan, an antimicrobial agent. Polymethylmethacrylate (PMMA) resin (Jet Acrylic (Lang Dental Mfg. co., inc.)), modified by the addition of triclosan (Fluka Biochemika: Irganon (Catalog Number: 72779-5G-F)) in concentrations of 0 wt% (control), 2.5 wt%, 5 wt%, and 10 wt%, was formed into discs (2 mm deep x 6 mm diameter) for testing. Similarly, composite resin (laboratory-formulated) in the same concentrations was formed into discs. All discs were subjected to Knoop hardness testing using an M-400 Hardness Tester and ACP-94 Digital Measuring Microscope. The load used on the indenter was a 50 gram force (gf) with indents made in the center and periphery of the discs. Five PMMA discs from each concentration were fabricated and sterilized with ethanol. Each disc was placed on a lawn culture of *Streptococcus mutans* prepared on blood agar plates. Observations of planktonic bacterial growth in broth and on the viability of biofilm cells with the triclosan-containing specimens were also demonstrated. The findings indicated that there was a significant decrease in microhardness of the 10% triclosan-incorporated composite resin group compared to that of the control group. There was no significant difference ($P = 0.550$) in microhardness among the four concentration groups of triclosan-incorporated PMMA groups. Increasing the triclosan concentration in composite resin significantly lowered the microhardness properties compared to that of the control group (0% triclosan in composite resin). Increasing the triclosan concentration (up to 10%) in temporary acrylic resins did not have a significant impact on microhardness properties of temporary acrylic resins. PMMA totally inhibits *S. mutans* biofilm formation. Funded by IUSD Grant.

P20 Micro-morphological Changes of a Glass-ceramic—Effects of Hydrofluoric Acid Etching
S. POSRITONG*, M.C. BOTTINO (Indiana University School of Dentistry)

Background: Numerous studies have reported the use of hydrofluoric (HF) acid as one of the most effective methods to achieve a high/durable bond between glass-ceramics and resin cements. The aim of this study was to evaluate the effect of different HF acid etching regimes on ceramic surface morphology by scanning electron microscopy (SEM) as well as the surface roughness (Ra and Rq, in μm) by 2D profilometry. Material and Methods: Twenty-four disc-shaped (15 mm in diameter \times 0.8 mm in thickness) ceramic specimens (IPS e.max Zirpress, eZir) were divided into 6 groups: G1-control (as-polished), G2-30s, G3-60s, G4-90s, G5-120s, G6-60+60s. For the re-etched groups (G6), the specimens were immersed in human saliva (IRB#0304-58) for one minute and then rinsed with distilled water (DI) and air-dried before the second etching procedure. After etching, all groups were rinsed with DI water, air-dried and allocated for roughness and morphological assessment. Roughness data were submitted to one-way ANOVA and Tukey's test ($\alpha=0.05$). Results: G1 (Ra=1.9 \pm 0.4 μm / Rq=2.3 \pm 0.4 μm) presented statistically higher ($p<0.0001$) Ra and Rq values when compared to all groups except G4 (Ra=1.9 \pm 0.4 μm / Rq=2.3 \pm 0.4 μm , [$p>0.05$]). Overall, G1, G4 showed the highest ($p<0.05$) roughness mean values (Ra and Rq) followed by groups G2, G3, G5 and G6 in a decreasing order. SEM micrographs revealed that eZir ceramic samples (G2-G6) became more porous suggesting glass-matrix dissolution after HF etching. G2 exhibited the smoothest surface pattern among the etched groups, while G3 and G4 showed more porosities and irregularities. G6 exhibited a more homogenous pattern than G5. Conclusion: Within the limitations of this study, our findings demonstrated that distinct HF etching regimes play an important role on altering the morphology/roughness of the ceramic. Further studies will need to be performed to investigate whether cleaning the specimens after etching (e.g., ultrasonic bath) could enhance roughness and improve resin-ceramic bonding.

P21 Resin-Coated Glass Ionomer Cement Abrasion and Wear Resistance. A. ALJAMHAN, J.A. PLATT*, N.B. COOK, M. COCHRAN, B.A. MATIS, A. FERREIRA ZANDONÁ (Indiana University School of Dentistry)

The objective of this study was to measure the abrasion/wear resistance and hardness of a resin coated high strength glass ionomer compared to other current restorative materials. Four materials were evaluated: EQUIA(EQ), Fuji IX GP Extra(IX), Fuji II LC(LC) and Z-100(Z1). EQ coating, Z1, and LC were activated with 820 mW/cm² using a LE Demetron II. Toothbrush abrasion specimens (2mm x 2mm x 25mm, n=6) were tested for 20,400 cycles and the amount of volume loss calculated. Alabama wear specimens (9.5mm diameter, n=8) were tested under a load of 75 Newtons for 400,000 cycles. Four surface profiles were obtained from each specimen and volume loss was calculated using integration. Wear specimens were finished through 800 grit SiC. Knoop microhardness specimens were made (6mm diameter x 1mm thick, n=5) and values determined using the mean of the three measurements from the top surface of the specimen. Specimens for all tests were stored at 37°C for 24h before testing. Data was evaluated using ANOVA, Tukey's, and Wilcoxon tests ($\alpha=0.05$). Abrasion loss ranged from 3.2-4.6 mm³ with LC>IX=Z1=EQ. Alabama loss ranged from 0.1-2.6 mm³ with LC>IX>EQ=Z1. Microhardness ranged from 24.2-82.3 KHN with Z1>IX>LC=EQ. Coating the surface of glass ionomer restorations with a nano-filled resin coat results in increased wear resistance and decreased microhardness of the material. Partially supported by GC America.

P22 Optimizing Light-cured Composite Properties with Camphroquinone and Butylhydroxytoluene Combinations. H.M. NASSAR*, T.G. CHU (Indiana University School of Dentistry)

Polymerization shrinkage is an inherent property in resin composite that has major effects on its clinical performance. Many strategies on minimizing the shrinkage, including new polymers and light curing dynamics, have been explored in the past. Here we propose that, by optimizing the dose combinations of photoinitiator and polymerization inhibitor, we can effectively reduce the polymerization shrinkage stress without sacrificing the mechanical properties of dental composite. The objective of this study therefore was to systematically investigate the effects of a common photoinitiator, camphroquinone (CQ), and inhibitor, butylhydroxytoluene (BHT), at clinically-relevant concentration combinations on the shrinkage properties and mechanical properties of light-cured composite resin. Samples were prepared by mixing Bis-GMA, UDMA, and TEGDMA at a 1:1:1 ratio. Borosilicate glass fillers constituted 70% of the resin weight. Sixteen groups of resin composite were prepared from the combination of four CQ (0.1%, 0.5%, 1.0%, and 1.5%) and four BHT (0.0%, 0.5%, 1.0%, and 1.5%) levels. For each group, six properties were tested, including Flexural strength (FS) flexural modulus (FM), degree of conversion (DC), contraction stress (CS), stress rate (SR), and gel point (GP). The effects of CQ and BHT combinations on each of these properties were evaluated using two-way analysis of variance (ANOVA). Groups with low CQ and BHT showed moderate values for FS, FM, SR and CS with DC around 70%. Increasing the BHT concentration caused a decrease in SR, CS, DC and an increase in GP values. Increasing the CQ content gave a steady increase in values for FS and FM. The results can be explained by the polymerization kinetics of the dental composites. Notable, in CQ=1.5% group, increasing BHT from 0 to 1.5% result in a statistically significant decrease in polymerization shrinkage stress ($p < 0.05$) while maintain the same mechanical properties. In this project, we successfully demonstrated that the polymerization shrinkage of resin composite can be tailored through CQ and BHT combinations with high CQ and high BHT showing the most promising results.

P23 Effects of Mandibular Positional Changes on Airway Dimensions. D. WARD^{1*}, K. KULA¹, G. ECKERT², A. GHONEIMA¹ (¹Indiana University School of Dentistry; ²Indiana University School of Medicine)

The aim of this retrospective study was to investigate the effects of mandibular positional changes on the airway dimensions in a group of orthodontic patients. Following reliability studies, lateral cephalometric radiographs of 118 Caucasian subjects, aged 8-15 years, were selected from the postgraduate orthodontic clinic archives and traced manually for different airway parameters. Each subject had two cephalograms taken on the same day. The cephalograms were classified into 2 groups according to the position of the mandible. Group 1 consisted of cephalograms taken with the mouth closed (teeth in centric occlusion) and group 2 consisted of cephalograms taken with the mouth open (maximum opening position). Intraclass correlations (ICC) were performed on duplicate measures of 10 cephalograms. Airway parameters were compared between the two groups using nonparametric Wilcoxon signed rank test. Statistical significance was set at $P < 0.05$. ICC values were >0.90 for all measures. Significant differences between the mandibular positions were found in most of the airway dimensions. The sagittal depth of the airway at the nasopharynx and oropharynx levels (PNS-ad1, PNS-ad2, PNS-ppw1, PNS-ppw2) and the vertical length of the airway (PNS-E) were significantly increased in group 2. The sagittal depth of the pharyngeal lumen at the level of the hypopharynx (apw4-ppw4) and the soft tissue thickness behind the posterior pharyngeal wall (Ba-ad1) decreased significantly when patients widely opened their mouth. These results suggest that increasing the vertical dimension by opening the lower jaw increases the upper airway dimensions in width and length and conversely decreases the lower airway width and the soft tissue thickness of the airway.

- P24 Digital Radiography: Its Clinical Applicability in the Pediatric Dental Setting.** A. ADAIR*, B. SANDERS, J. JONES, L. WALKER, J. WEDDELL, A. TOMLIN, M. VAN DIS (Indiana University School of Dentistry)

The use of digital radiography has increased in dental practices. Published literature on digital imaging is focused primarily on adult dentition. Minimal research exists on the clinical applicability of digital radiographs in the pediatric dental population. The purpose of this study was to provide an update on the percentage of practicing pediatric dentists using intraoral digital radiography and to investigate the techniques utilized when obtaining digital imaging in the pediatric dental population. An electronic questionnaire was sent to members of the American Academy of Pediatric Dentistry. The response rate for this survey was 18.2%. Responses were summarized using frequencies and percentages. 74% of respondents reported using all or mostly digital imaging for intraoral radiographs. 93% of digital users have been in practice 0-10 years. Of the digital users, 61% reported using direct digital imaging systems whereas 39% reported using indirect digital imaging systems. The data reflects that the use of digital imaging has increased compared to previous reports. More pediatric dentists currently use direct digital imaging than indirect digital systems.

- P25 Degradation of Resilon/RealSeal™ by Bacteria Found in Endodontic Infections.** Y. EHRlich*, J.J. WHATLEY, R. HUANG, M. LI, F. LIPPERT, K.J. SPOLNIK, R.L. GREGORY, (Indiana University School of Dentistry)

Objectives: Resilon/RealSeal (RS) is a resin based obturating material that claims to create a chemical bond between the dentin of the walls of the root canal, the sealer and the thermoplastic core material. It attempts to create a “monoblock” of material that will seal the root canal system. RS is comprised of a biodegradable polymer, polycaprolactone and inorganic fillers, and has been shown to undergo degradation/hydrolysis by bacterial enzymes such as lipase. This study aims to demonstrate if bacteria observed in persistent AP can degrade RS using an agar disc hydrolysis method previously described. Methods: A RS emulsion was prepared and dispersed to make 0.1% RS in 1.5% Tryptic Soy Agar plates. Similar volumes of overnight cultures of *P. intermedia*, *P. aeruginosa*, *P. asaccharolytica*, *S. aureus*, *S. epidermis*, *E. faecalis*, *F. nucleatum*, *S. mutans*, *S. sanguis* and *P. gingivalis* were each inoculated in 8 spots on the agar plates. The bacterial enzyme Lipase PS (*Burkholderia cepacia*) served as a positive control. Results: *P. intermedia*, *P. aeruginosa*, *P. assacharylitucus*, *S. aureus* and *S. epidermis* all demonstrated hydrolytic halos at each of the 8 inoculation locations (100%) these bacteria were plated (95% CI 63%-100%). The halos were similar to those seen with the positive lipase control and indicate hydrolysis of RS. The halos further developed with time as the colonies grew to a size of 6-8 mm in diameter after 4 days. No halos were seen with *E. faecalis*, *F. nucleatum*, *S. mutans*, *S. sanguis*, or *P. gingivalis* at any of the 8 inoculation spots (0%) these bacteria were plated (95% CI 0%-37%). Conclusion: Bacteria found in endodontic infections can hydrolyze RS dispersed into an emulsion. A potential exists for RS degradation in persistent/secondary endodontic infections.

- P26 Approaches to Papillomavirus Detection.** E. COLE^{1*}, J. JOH², S.J. GHIM², M. PROCTOR³, A. JENSON² (¹School of Dentistry; ²School of Medicine; ³Research Resources Center; University of Louisville)

Objectives: Papilloma virus (PV) infections are typically species and site specific. We obtained frozen tissue from a canine anogenital lesion and our objectives were to; 1) test an effective PCR---based technique for HPV detection in this tissue and, 2) apply full--- genome analysis to identify the canine PV subtypes that were present in this anogenital tissue sample. Methods: DNA was isolated from the frozen---tissue biopsy sample. Subsequent amplification was accomplished by the multiply primed rolling---circle

technique to obtain the viral plasmid. The circular DNA was linearized and cloned into a pUC19 vector. Genomic sequencing and phylogenetic comparison was completed using DNASTar software. Results: Whole viral genome isolation from the canine anogenital biopsy indicated the presence of a canine oral papillomavirus (COPV). Conclusion: Using whole genome purification and analysis, we identified a novel anogenital tropism for COPV, indicating that COPV may represent a model that can be applied to develop a cervical cancer vaccine. In addition, this approach for PV Identification emphasizes the simplicity of PV Detection and highlights the power of molecular biology to inform the clinician.

P27 Construction of 3D Tooth Models for Endodontic Research and Education. T. YOSHIDA*, J. SUN, S. LIU, J.A. PLATT (Indiana University School of Dentistry)

Objective: To perform endodontic therapy, it is necessary to identify the 3-dimensional root canal morphology, for which abundant clinical experience is necessary because the morphology varies among patients. However, it is difficult to imagine the 3-dimensional morphology from 2-dimensional images presented in text books. In this study, 3D tooth voxel models were established from CT images for utilization endodontic research and education. Methods: Extracted human teeth were subjected to micro CT (Skyscan1072, Skyscan) and reslicing was accomplished using reconstruction software (Nrecon, Skyscan). Artifacts and noises were removed using image-processing software (Photoshop CS, Adobe). Rectified images were converted into a voxel model. Voxel models were prepared using visualizing software (Micro AVS 10.0, KGT). Furthermore, the voxel models were prepared from original teeth, after root canal enlargement after root canal obturation, and then compared to observe the treatment conditions. Results: The visualized voxel models facilitated observation of the pulp cavity from any angle. In the models after root canal enlargement, the conditions such as funnel enlargement and apical stop could be stereoscopically observed. In the models after root canal obturation, sealer and gutta-percha were separated based on the difference in the X-ray transmission coefficient, and the condition after each obturation could be observed. Conclusion: Using the 3D tooth voxel model, the condition after treatment could be stereoscopically observed, which was previously impossible. The success or failure of root canal enlargement and obturation can be clearly presented to students using this model, showing its usefulness as a new tool for endodontic research and education. Supported, in part, by the IUPUI 3D ICCC signature initiative.

P28 Evaluation of Videogame Experience and Hand Eye Coordination. P. JAKUBOWICZ*, S. CHO, B. ADAMS (Indiana University School of Dentistry)

Hand eye coordination is essential in Dentistry. As a result, students must demonstrate sufficient hand eye coordination in preclinical courses in order to being promoted in the curriculum. Laboratory practical examinations e.g. waxing and tooth preparation are the examples of the evaluation methods. This study was to examine the relationship between hand eye coordination; waxing competency, with previous videogame experience of the first year dental students. The students were asked if they play videogames and, if yes, the amount of time per week and the type of videogame played were also recorded. The surveys were distributed twice among the students. Data was then statistically analyzed. Students who play videogames and those who do not play video games did not have significantly different practical exam scores (p=0.45 practical 1, p=0.14 practical 2, p=0.82 for average of practical 1 and 2). Number of hours playing video games did not have a significant effect on practical exam scores (p=0.94 practical 1, p=0.34 practical 2, p=0.80 for average of practical 1 and 2). Type of game played did not have a significant effect on practical exam scores (p=0.66 practical 1, p=0.75 practical 2, p=0.94 for average of practical 1 and 2). The results suggest past videogame experience is not a good indicator of hand eye coordination. Future larger study is needed to have a better statistical power. Supported by Student Research fund.

P29 Dental Implant Placement in HIV Positive Individuals: A Case Series. S. ALYAS*, S. KOLHATKAR (University of Detroit Mercy School of Dentistry)

Objectives: The life expectancy of patients with human immunodeficiency virus (HIV) continues to increase due to advancement in Highly Active Antiretroviral Therapy (HAART). Therefore, the philosophy of treating HIV positive (HIV+) patients has shifted from primarily managing dental emergencies to providing comprehensive dental care, including implant therapy. The impression of some individuals is that the weakened immune status of HIV+ patients, the altered bone metabolism, as well as some of local and systemic factors that are associated with HAART, may increase the potential risk of implant failure. This case series aims to evaluate the healing pattern of implants after placement in HIV+ individuals. Methods: Four adult male HIV+ patients, ranging in age from 40 to 57, were included in this case series. These patients were current smokers, past smokers, and non-smokers. All patients were undergoing HAART therapy. A total of five implants (4.1mmx10mm-5mmx10mm) were placed in the mandibular arch in a delayed manner. The implants were restored between 4 – 12 months with single porcelain fused to metal crowns and a splinted full coverage gold crown in one of the cases. Results: The post-operative healing following implant placement was uneventful with absence of pain, infection, exudate, or swelling. After restoration of the implants, the patients were followed for 6 - 36 months. Clinical and radiographic examination revealed stable bone levels and absence of peri-implant radiolucency or mobility. Conclusion: This case series indicates that placement of implants has a predictable outcome in HIV+ individuals, making it a viable treatment option for this population group. This case series adds to the body of knowledge and evidence supporting implant placement in HIV+ individuals. A larger clinical trial with a longer follow up will aid in adding to information about the management of partially or completely edentulous HIV+ patients using implants.

P30 Niobium Oxide Coating Enhances Osseointegration of Titanium Implants. J. AU-YEUNG*, T.G. CHU (Indiana University School of Dentistry)

The purpose of this study was to evaluate the effects of a niobium oxide (NbO) coating on the in vivo performance of titanium implants. Forty screw-type dental implants made from commercially pure (CP) titanium, 3.5 mm in diameter and 5.5 mm in height, were obtained. Half of the implants were coated with niobium and anodized by Indiana Nanotech using 0.5% hydrofluoric acid (HF) at 25V to create a NbO coating. Ten New Zealand white rabbits weighing 3.5-4.5 kg received implants. Each rabbit underwent surgery to receive four implants, two per tibia. Five rabbits were implanted on the right tibia with one NbO coated implant placed proximally and one uncoated control implant placed distally, with the reverse arrangement on the left tibia. The remaining five rabbits were implanted in the opposite configuration to control for potential differences in removal torque due to implant location. The animals were sacrificed 6 weeks after implant placement. The sections of tibia extending 5 mm distally and 5 mm proximally to the implants were obtained en bloc for examination. Ten NbO coated and ten uncoated implants were tested for removal torque using a digital torque gauge. The remaining samples (n=10 each, coated and uncoated implants) were embedded undecalcified in polymethyl methacrylate, sectioned, and then stained with McNeals Tetrachrome (von Kossa followed by toluidine blue) to detect mineralized tissue. There was a statistically significant 61.42% increase ($p < 0.05$) in the removal torque of the NbO group compared to the CP titanium control group (32.30 \pm 9.13 Ncm vs 20.01 \pm 7.62 Ncm, respectively). In both groups histological analysis demonstrated new bone growth between the original cortical bone and the implant, forming an intimate contact with the implant surface. However, under histomorphometric analysis, there were no significant differences in the bone to implant contact (BIC) of the control implants compared to the NbO-coated implants (66 \pm 18% and 71 \pm 21%, respectively, $p > 0.05$). There were no statistically significant differences in the BIC between NbO coated and uncoated implants, the removal torque for the NbO-coated implants was significantly higher. The results may indicate that the bonding between bone and a NbO coating is higher than the bonding between bone and an uncoated titanium surface. The

findings from this study are valuable in the development and manufacturing of a novel NbO implant surface that improves osseointegration and outcomes of implant therapy.

P31 Blood Contamination of Used Dental Anesthetic Cartridges. E.R. SVETANOFF*, L.M. ROMITO, C.J. PALENIK (Indiana University School of Dentistry)

Currently, OSHA does not consider used dental anesthetic cartridges as being a type of regulated medical waste. This position is based on a small study in which a low percentage of cartridges examined had evidence of visible blood. The objectives of this study were to determine the levels of blood contamination in/on used dental anesthetic cartridges and to measure antibacterial effects after exposure to a local anesthetic solution. Involved were 1000 used cartridges of three anesthetic types coming from an oral surgery clinic. Blood testing involved both visual observations using a dissecting microscope and chemical analyses. Removed from each cartridge was either 0.5 mL of residual anesthetic solution or a combination of anesthetic solution plus added saline. All solutions underwent analyses for minute amounts of blood using *Hemastix* test dipsticks. Scoring of visual examinations was on a “positive” or “negative” basis. Scoring included development of a blue color with values varying from “zero” through “six.” Lidocaine or physiological buffered saline (PBS) was mixed with four types of bacteria for exposure periods up to 30 days. Decreases in viable cell counts between the two solutions were measured. Only 7 of the 1000 cartridges examined contained visible blood. Most cartridges (78.67%) evaluated contained lidocaine. Over 76% of all cartridges contained blood as detected by *Hemastix* testing. Exposure to lidocaine over time produced bacterial death rates similar to those produced by PBS. Levels of blood contamination in the absence of pronounced antibacterial activity support the position that dental anesthetic cartridges could be considered as a potential type of regulated medical waste.

P32 Resolvin-D1 Blocks the Effects of *Porphyromonas Gingivalis* on Human Gingival Fibroblasts. M. KHALED*, N. LABBAN, N.K. AL-SHIBANI, E. ALLAM, G. BATERSEH, L.J. WINDSOR (Indiana University School of Dentistry).

Periodontitis is an immune inflammatory disease that is initiated by bacteria and the destruction is caused largely by host responses. *Porphyromonas gingivalis* (*P. gingivalis*) is a periodontal pathogen that affects cells in the periodontal tissues such as gingival fibroblasts. Resolvins are novel molecules that protect the host against acute inflammation in part by blocking the trans-endothelial migration of neutrophils and initiates resolution. Oxygenated metabolites derived from docosahexaenoic acid are resolvins of the D series. Data is limited about the effects that resolvins have on other cells in the periodontal tissues. Human gingival fibroblasts (HGFs) are present in these tissues and play critical roles in tissue remodeling and repair, as well as in tissue degradation. The aim of this study was to determine the effects that Resolvin-D1 has on HGF cell survival and cytokine/growth factor expression when treated with and without *P. gingivalis*. Lactate dehydrogenase assays were utilized to determine the cytotoxic effects of Resolvin-D1 on HGFs with and without 13.5% *P. gingivalis* supernatant. Cytokine/growth factor protein arrays were performed on conditioned media from human gingival fibroblasts treated with and without Resolvin-D1, as well as with and without 10% *P. gingivalis* supernatant. Resolvin-D1 had no cytotoxic effects on the HGFs at concentrations between 1-1000 nM (all p values ≤ 0.05). Resolvin-D1 (1000 nM) significantly inhibited the toxic effects of 13.5% *P. gingivalis* supernatant (p= 0.002) on HGFs. Resolvin-D1 altered the expression of pro-inflammatory cytokines/growth factors from *P. gingivalis* treated HGFs. Resolvin-D1 altered the toxicity of a toxic level of *P. gingivalis* supernatant on HGFs. The ability of Resolvin-D1 to down regulate pro-inflammatory cytokine/growth factors might be utilized in preventing conditions such as periodontal disease.

P33 Salivary Epithelial Cells: a Model to Study Host-Biofilm Immune Response. T. NEGRINI^{1*}, D. SATHYANARAYANA², S. JANARDHANAM², I. CARLOS¹, R. ARTHUR², M. SRINIVASAN². (¹Araraquara School of Pharmaceutical Sciences; Sao Paulo State University, Brazil; ²Indiana University School of Dentistry)

Chronic inflammatory diseases contribute significantly to decreasing health in humans. Many chronic inflammatory conditions begin as a response to the normal microbial flora in constant contact with the host cells. The initial response is mediated by a group of proteins called the toll like receptors (TLR) that recognize specific patterns typically shared by a group of microorganisms. TLR-2 primarily recognizes the peptidoglycan in the cell wall of Gram-positive bacteria. Previously we have observed that the epithelial cells isolated from the saliva of individuals with chronic periodontitis express reduced levels of TLR-2 as compared to that from healthy individuals. Preliminary data suggest that the salivary epithelial cells cultured in-vitro in the presence of a biofilm with common oral bacteria responded by secreting chemokines. This suggested that the salivary epithelial cells could be used as biospecimen to investigate host-microbial interactions. In this study we evaluate the response of salivary epithelial cells to common cutaneous pathogens. Salivary epithelial cells collected from a healthy donor were cultured on medium supplemented with antibiotics until formation of a monolayer of cells. Dual-species biofilms formed by *Staphylococcus aureus* and *Staphylococcus epidermidis* were grown on nitrocellulose membrane in glucose enriched medium. The membranes collected after three days were serially diluted and plated on non-selective agar plates for counts of viable cells. On the day before biofilm collection, epithelial cells were cultured in antibiotic-free medium, seeded on 12 well-plates (10^5 cells/well) and incubated for 16 hours. Membranes containing biofilms were then co-cultured with salivary epithelial cells for 4 and 6 hours. Total RNA isolated from epithelial cells was amplified for TLR-2 by quantitative real time polymerase chain reaction (RT-PCR). Amplification of b-actin was performed as controls for PCR reaction. The small-proline-rich-protein gene (SPRR) abundantly expressed in epithelial cell was amplified for specificity. The biofilm grown on nitrocellulose membrane exhibited approximately 10^5 and 10^8 CFU/mm² of *S. epidermidis* and *S. aureus*. Quantitative RT-PCR suggested higher expression of TLR-2 in epithelial cells co-cultured with dual species biofilm as compared to that in the unexposed epithelial cells. These results suggest that salivary epithelial cells may be used as a useful model to study the innate immune response against cutaneous pathogens.

P34 Interactions of Human Gingival Fibroblasts with Tobacco Treated *Porphyromonas Gingivalis*. B. LANIER^{1*}, N.K. AL-SHIBANI², L.J. WINDSOR², R.L. GREGORY² (¹Indiana University-Purdue University Indianapolis; ²Indiana University School of Dentistry)

Porphyromonas gingivalis and tobacco are risk factors for periodontal disease. The objective of this study was to determine the effects that tobacco treated *P. gingivalis* cells have on human gingival fibroblasts (HGFs). The study was conducted to examine the effects that cigarette smoke condensate (CSC), nicotine, and dissolvable smokeless tobacco (DST) strips treated *P. gingivalis* has on cell cytotoxicity and the expression of cytokines and growth factors from HGFs. The *P. gingivalis* was grown at 37°C and then the cells and supernatant were separated. *P. gingivalis* cells were then washed and killed. The concentration of protein in the cell pellet and supernatant were determined by protein assay using the Bradford method. The lowest non-toxic levels of the cell pellet and supernatant will be used to treat the HGFs for 72 hours and then cytotoxicity was determined by lactate dehydrogenase (LDH) assays. The cytokine/growth factor expression will be determined by antibody protein arrays. The protein assays showed that the tobacco products reduced the protein amounts as compared to untreated bacteria. The results should show an increase in cytotoxicity with increasing protein concentrations, along with increased pro-inflammatory cytokine/growth factors expression by the HGFs treated with tobacco treated *P. gingivalis* compared to *P. gingivalis* that was not treated with tobacco products. A better understanding of the detrimental effects that tobacco has on the underlining causes of periodontal disease can advance the quest of controlling the

disease. This study was funded by the Indiana University-Purdue University Indianapolis Multidisciplinary Undergraduate Research Institute (MURI).

P35 The Effects Of Tobacco Treated *Porphyromonas Gingivalis* On Human Epithelial Cells. R. TURSUNOVA*, N.K. AL-SHIBANI, L.J. WINDSOR, R.L. GREGORY (Indiana University School of Dentistry)

Bacteria and tobacco are risk factors for periodontal diseases. Bacteria-host interactions play a critical role in disease development and progression. The effects of tobacco-treated bacteria such as *Porphyromonas gingivalis* on epithelial cells have not yet been examined. Therefore, *P. gingivalis* were treated with different tobacco products (nicotine, cigarette smoke condensate (CSC), and dissolvable smokeless tobacco (DST) strips) to determine the effects that they have on epithelial cells. *P. gingivalis* were grown with or without the products for 24 hours at 37°C. The cells were separated from the supernatant, washed with 0.9% NaCl and incubated at 60°C to kill the bacteria. Protein assays were performed to determine the protein concentration in the cell pellets and supernatants. Lactate dehydrogenase (LDH) assays are being used to measure the cytotoxicity of the cells and supernatants on epithelial cells in a dose dependent manner. Non-toxic amounts of the cell pellets and supernatants will be used to treat epithelial cells for 72 hours and the media analyzed by cytokine/growth factor protein arrays. The protein assays showed that CSC and nicotine treated *P. gingivalis* cells had less protein than the others. The total protein in the supernatant for the CSC treated bacteria was less compared to others. The protein data suggests that CSC and nicotine affect protein expression in and by the *P. gingivalis* cells. Tobacco-treated bacteria are hypothesized to increase the expression of pro-inflammatory cytokines/growth factors by the epithelial cells, thereby contributing to the inflammation seen in periodontal diseases.

P36 Influence of Tea Polyphenols and Nicotine on *Streptococcus mutans* Growth. J.A. FOLTZ^{1*}, M. LI², R. HUANG², R.L. GREGORY² (¹Indiana University School of Medicine; ²Indiana University School of Dentistry)

Objectives: Tea polyphenols have antimicrobial effects. Epigallocatechin gallate (EGCG) and epicatechin gallate (ECG) are polyphenols present in green and black tea. *S. mutans* is a cariogenic bacterium. People who smoke tend to have more caries than non-smokers. Nicotine increases *S. mutans* growth at low concentrations. The objective of this study was to measure the effect of tea polyphenols on *S. mutans* growth in the presence of nicotine. Methods: *S. mutans* UA159 was treated with nicotine (0-8 mg/ml), EGCG (0.25 mg/ml), and ECG (0.25 mg/ml) in combination with and without nicotine. Growth effects were measured kinetically in microtiter plates over a 12h period. Lag time, time to maximal absorbance (T_{max}), maximal absorbance, and maximal velocity (V_{max}) of planktonic cells were measured. Biofilm formation was measured using a crystal violet dye staining assay. Results: *S. mutans* exposed to nicotine and EGCG demonstrated significantly increased T_{max} (0-1 mg/ml of nicotine; $p < 0.05$) and a decrease in V_{max} (0-1 mg/ml) in planktonic cells. *S. mutans* exposed to ECG and nicotine displayed an increase in T_{max} (0.25-1 mg/ml) and a decrease in V_{max} (0- 2 mg/ml). Biofilm formation of *S. mutans* with EGCG and nicotine exhibited a decrease in biofilm formation at 0.25, 1, 2, and 4 mg/ml of nicotine. Biofilm formation of *S. mutans* with ECG and nicotine demonstrated that ECG abrogates nicotine's effect on *S. mutans* growth (0.25-4 mg/ml). Conclusions: These results suggest that both EGCG and ECG slowed the growth of planktonic *S. mutans* with no nicotine and at low concentrations of nicotine. EGCG exhibited a biphasic response on biofilm formation. ECG diminished nicotine's stimulatory effect on *S. mutans* in biofilm formation. This study provides evidence for the beneficial aspects of tea polyphenols on *S. mutans* treated with nicotine.

P37 Effect of Caffeine on *Streptococcus mutans* Planktonic Growth, Biofilm formation and Metabolic Activity. R. GARDNER*, M. LI, R. HUANG, R.L. GREGORY (Indiana University School of Dentistry)

Streptococcus mutans is the main bacterial cause of dental caries, and it has been shown in previous research that its growth is affected by various levels of nicotine and other agents. The concentration of *S. mutans* is directly proportional to the number of dental caries in the mouth. Research in our lab and others has been shown that smokers have increased dental caries due to the nicotine being a promoting agent for *S. mutans* growth. Due to dental plaque bacteria being introduced into the bloodstream, *S. mutans* has also been proven as a cause of cardiovascular disease. It has been observed that many people while smoking, are drinking some particular caffeinated beverage, usually coffee. Previous research has determined that coffee reduces dental caries as it interferes with *S. mutans* ability to adhere to the tooth surface. Although research on the effects of caffeine on *S. mutans* is not completely clear, it has been suspected that caffeine is an inhibitor of *S. mutans*. The objective of this research was to observe how caffeine affects *S. mutans* planktonic and biofilm growth and biofilm metabolic activity. The planktonic growth curves of *S. mutans* were studied using various concentrations of caffeine as well as studying the effects of caffeine on *S. mutans* biofilm formation and metabolic activity. These experiments concluded with results proving that caffeine acts as an inhibitor of *S. mutans*. The amount of caffeine in one cup of coffee, 6 mg/ml, significantly retards planktonic growth, and inhibits biofilm formation. The higher concentrations of caffeine inhibit *S. mutans* more effectively than the lower concentrations (.075 mg/ml). However, even at the lowest concentration of caffeine used, *S. mutans* growth was significantly inhibited. These results provide evidence for the inhibitory effect of caffeine on *S. mutans* biofilm and may indicate a mechanism for the effect coffee has on reduction of caries.

P38 Effect of Tobacco-Treated *Porphyromonas gingivalis* on Human Pulp Cells. S. GEBRESLASSIE*, R. HUANG, M. LI, F. SONG, R.L. GREGORY (Indiana University School of Dentistry)

Objective: The objective of this study is to determine the effects of tobacco products on protein concentration and growth of *Porphyromonas gingivalis* and the effects of the bacterial cells and culture supernatants on human pulp cells. The study was designed to observe the effects of *P. gingivalis* grown in four different tobacco solutions such as CSC (cigarette smoked condensate), nicotine (chewing tobacco), and DST (dissolvable smokeless tobacco) strips, and in the media control only without tobacco products. Methods: *P. gingivalis* was grown in BHI-YE (Bacteria Heart Infusion-Yeast Extract) and hemin-vitamin K. In addition, *P. gingivalis* was grown in BHI-Y-E containing nicotine, CSC, and DST. Human pulp cells were grown in media containing BGS (Bovine Growth Serum) and washed. The pulp cell cultures will be assayed for cytotoxicity and the supernatants will be assayed for cytokines and MMP expression. Results: The protein assays was performed using a microplate spectrophotometer and SoftMax Pro 5.2, and we observed that nicotine and DST treated cells had significantly less protein than control cells, however, CSC treated cells had significantly more protein. The undiluted control supernatant had significantly less protein than the tobacco-treated supernatants. Conclusion: Based on the previous experiments, we speculate that the additional protein in the undiluted CSC cells and tobacco-treated supernatants may stimulate more effect on human pulp cells than the control, nicotine or DST treated cells or the control supernatant.

P39 Prostacyclin Mediates the Neuroprotective Role of Cyclooxygenase-2. Y. AN*, N. BELEVYCH, Y. WANG, N. POWELL, Q. CHEN, N. QUAN (The Ohio State University College of Dentistry)

Although a large body of literature suggests that the expression of cyclooxygenase-2 (COX-2) augments acute brain injury, COX-2 dependent neuroprotection has also been reported. One possibility to explain the apparent opposite effects of COX-2 is that COX-2 expressed in different cell types may mediate different effects. In this study, we analyzed the effects of cell type specific deletion of COX-2 in a mouse model of excitatory neural injury. An NMDA receptor agonist was injected into the striatum. In WT mice, COX-2 was induced in two groups of cells, distal neurons on the cortex near the injured site and non-neuronal cells that associated with blood vessels in the injured tissue. In contrast, in Tie2-Cre COX-2^{flox/flox} mice, a conditional COX-2 KO, only neuronal COX-2 expression was induced. Administration of COX-2 specific inhibitor prior to the NMDA agonist injection significantly reduced the lesion volume in both the WT and the conditional COX-2 KO mice. Further, injection of an antagonist to the receptor of PGE₂ (a product of COX-2) reduced lesion size in both animal groups, suggesting the neurotoxic effects of COX-2 is mediated by neuronal production of PGE₂. Surprisingly, the lesion volume induced by the NMDA agonist injection in the conditional KOs is twice as large as that induced in the control mice. It suggests that the neuroprotective role of COX-2 expression in non-neuronal cells. Meanwhile, the level of PGI₂, another COX-2 catalyzed prostaglandin, was induced by NMDA agonist in WT mice but remained unchanged in KO mice. Immunohistochemistry also showed that PGI₂ producing leukocytes infiltrated into the lesion brain parenchyma in WT mice but not in KO mice. In addition, inhibition of the PGI₂ synthesis in the WT animals also induced an increase in the lesion size, whereas injection of PGI₂ agonist into the conditional KOs reduced the lesion size. Thus the expression of COX-2 in non-neuronal cells appears to exert neuroprotective effects via the action of PGI₂. Non-neuronal COX-2 expression is required for the recruitment of PGI₂ producing leukocytes to the injured brain.

P40 The Effect of Nicotine on *Streptococcus mutans* Anaerobic Growth. R.L. GREGORY¹, M.A. ALDOSARI¹, R. HUANG¹, M. LI¹, A.M. ALDOSARI² (Indiana University School of Dentistry; ²King Saud University, Riyadh, Saudi Arabia)

Objectives: The relationship between dental caries and *Streptococcus mutans* is well known. We have earlier demonstrated that nicotine stimulates *S. mutans* growth and biofilm formation. *S. mutans* is a facultative anaerobe and can grow on occlusal surfaces (aerobically) and subgingivally (anaerobically) contributing to root caries. All previous studies on *S. mutans* in relation to nicotine were done aerobically. It is the aim of this study to assess the behavioral difference of *S. mutans* UA159 in an anaerobic environment at different nicotine concentrations. **Methods:** The behavioral aspects that were assessed included sucrose-induced biofilm formation, saliva-induced biofilm formation, metabolic activity, growth kinetics and growth kinetics with H₂O₂ (0.5 and 16.3 mM). The nicotine concentrations investigated in this study ranged between 0.00-32.00 mg/ml. **Results:** It was found that biofilm formation in sucrose or saliva medium was significantly better (p<0.05) anaerobically (highest at 8 and 2 mg/ml, respectively) while the presence of oxygen enhanced the metabolic activity of UA159 in a nicotine-dependent concentration manner up to 16 mg/ml. Growth kinetics indicated slower growth of *S. mutans* aerobically with a maximum absorbance at 0.25 mg/ml of nicotine concentration. With 0.5 mM H₂O₂ the maximum absorbance was noticed in the total absence of nicotine, but no growth was noticed at 16.3 mM. **Conclusion:** The absence of oxygen leads the *S. mutans* to behave differently with some enhanced abilities (biofilm) and some others suppressed (metabolic activity) at different concentrations of nicotine. This suggests that the different microaerophilic environments that *S. mutans* may grow in will stimulate various effects on the biofilm and growth characteristics of the bacterium.

P41 Interactions of Human Oral Cells with Oral Bacterial Cells. K.S. HEEKE*, R.L. GREGORY, F. SONG, L.J. WINDSOR (Indiana University School of Dentistry)

Introduction: *Streptococcus mutans* is the main etiological cause of dental caries, and it has been shown that individuals who smoke have increased dental caries. *S. mutans* is known to bind to or interact with gingival pulp fibroblasts. However, very little is known about the effects of tobacco directly on these bacteria on their ability to affect human pulp fibroblasts. We are hypothesizing that tobacco upregulates the expression of pro-inflammatory cytokines and MMPs to increase the pathogenic potential of *S. mutans*. The objective of this research project is to investigate the effects that nicotine, cigarette smoke condensate (CSC), and dissolvable smokeless tobacco (DST)-extract treated bacterial cells have on human pulp fibroblast cells, in respect to their release of pro-inflammatory and anti-inflammatory cytokines, as well as MMP expression. In addition, the effects of the *S. mutans* cells will be examined for the ability to affect pulp cell growth. The long-term goal is to develop treatment modalities to reduce the effects of smoking on dental caries. Materials and Methods: *S. mutans* UA159 was incubated in Tryptic Soy Broth (TSB), with the following concentrations: 2 mg/mL nicotine, 0.125 mg/mL CSC, 100 uL/3 mL DST-extract, and a 0 mg/mL control group. The cultures were grown in the presence of the tobacco products for 8 h at 37°C in 5% CO₂, and centrifuged to isolate cells and supernatants. The cells were washed and heat-killed for 1 h at 60°C. Human pulp fibroblast cells were isolated from extracted teeth, and cell passages 3-8 will be used. The tobacco-treated *S. mutans* cells and supernatants will be incubated with the fibroblasts in culture plates for 72 h and cytokine expression evaluated by reverse transcriptase polymerase chain reaction. Results: The protein concentration of each tobacco-treated sample was found. The undiluted concentrations of the nicotine- and CSC-treated cells were slightly lower and the DST-treated cells was slightly higher than the control cells. The undiluted nicotine (p<0.05) and DST-treated supernatants were higher than the control, while the CSC supernatant protein concentration was lower. From our previous studies, it was found that nicotine increases bacteriocin production of *S. mutans*, so we might hypothesize that nicotine induces bacteriocin secretion, thus increasing dental caries.

P42 Effect Of *Porphyromonas Gingivalis* Treated with Various Cigarette Constituents on Human Umbilical Vein Endothelial Cells. V. GUPTA^{1*}, L.J. WINDSOR², R.L. GREGORY² (¹Indiana University-Purdue University Indianapolis; ²Indiana University School of Dentistry)

Tobacco and cigarette smoke has known effects on the cardio-vascular system and has shown a marked increase in the rate of cardiovascular disease among smokers. However, the effect of cigarette smoke and tobacco on the endothelial cells that line blood vessels is not yet fully understood. Thus, the objective of this study is to understand the effect of the interactions between bacterium *Porphyromonas gingivalis* (*P.gingivalis*) and cigarette constituents such as cigarette smoke condensate (CSC), nicotine, and dissolvable tobacco strips (DST) on human umbilical vein endothelial cells (HUVEC's). *P.gingivalis* was grown initially in a blood agar plate (BAP) in an anaerobic environment at 37°C. Later, the bacteria were transferred to a BBL broth supplemented with 5% vitamin K & hemin serum in the same environment. Then, CSC, DST, and nicotine were added to the bacterial samples and cells and supernatant were harvested 96 hours later. A BIORAD Bradford protein assay was conducted on the supernatant cells at original concentration and 1:100 dilutions and absorbance was read at 595nm. The HUVEC were cultured in Endothelial Basal Medium-2 and plated in 6 well plates and exposed to the *P.gingivalis* treated bacterium. Lactate dehydrogenase (LDH) assay was conducted on the HUVECs to determine the cytotoxicity of *P.gingivalis*. The Students t-test was conducted and a significance of 5% was required for samples to be considered significant. In conclusion, past studies have indicated that there was synthesis of negative effects of *P.gingivalis* and tobacco constituents in the HUVECs. In *P.gingivalis*, absorbance significantly decreased in the DST. The opposite trend was present, but not significant in CSC and nicotine test samples. This study was funded by the Indiana University-Purdue University Indianapolis Multidisciplinary Undergraduate Research Institute (MURI).

- P43 Effects of Nicotine on Quorum Sensing in *Streptococcus mutans*.** E. BIKORIMANA^{1*}, R. HUANG², M. LI², R.L. GREGORY² (¹Indiana University-Purdue University Indianapolis; ²Indiana University School of Dentistry)

Streptococcus mutans is gram-positive cocci, facultative anaerobic bacterium commonly found in the human oral cavity, and significantly contributes to caries. The quorum sensing system plays an important role in microbial cell-cell interactions that leads to development of dental plaque. *S. mutans* produces glucosyltransferases together with the glucan binding proteins in order to facilitate the adherence of glucans to the tooth surface, thereby forming biofilms. Moreover, previous studies indicate that in the presence or absence of sucrose, a cell surface protein called antigen I/II plays an important role in the adherence process of *S. mutans*. There is a relationship between smoking and dental caries, in which the smoking population has a higher incidence of dental caries than a non-smoking population. Nicotine is one of the most important components in tobacco. In this study we investigated the effects of nicotine on quorum sensing in *S. mutans*. An *S. mutans* wild type UA159 and its knockout mutants defective in *comC*, *comD* and *comE* were used to investigate planktonic cell growth, the biofilm formation and biofilm metabolism at different concentrations of nicotine (0-32 mg/ml). The effects of nicotine on quorum sensing for *S. mutans*' biofilm formation was evaluated using sucrose-dependent and sucrose-independent assays. The results indicate that *S. mutans* UA159 and its knockout mutants had no substantial differences in planktonic cell growth. In the presence of sucrose, the *comC* mutant was unable to produce biofilms, whereas the biofilm formation and biofilm metabolism of the *comD* and *comE* mutants were enhanced with increased nicotine concentration as with UA159 up to 8 mg/mL of nicotine. However, in the absence of sucrose, it was observed that the *ComC* mutant formed biofilms relatively similar to UA159. Biofilm formation in the *comD* and *comE* mutants was also enhanced with the increase of nicotine concentration up to 4 and 2 mg/mL, respectively. The results suggest that nicotine enhances the adherence process in *S. mutans* by antigen I/II through the comDE signaling pathway. However, the fact that the *comC* mutant produced biofilm in the absence of sucrose, but not in the presence of sucrose, indicates that the activity of antigen I/II is activated through different cell-cell signaling pathways depending on the amount of sucrose present.

- P44 *Streptococcus mutans* UA159 Acid Survival in a 0.1M Glycine Environment.** R. CHAUDHARI*, R. HUANG, R.L. GREGORY (Indiana University School of Dentistry)

Streptococcus mutans is an anaerobic gram-positive bacterium known to cause dental caries. It is continuously submitted to a cycle of high and low pH environments in the oral cavity due to carbohydrate digestion. Using the UA-159 strain we set out to determine the survival of the bacteria when exposed to a low acidic environment of pH 2.5, 0.1M glycine solution. Cells obtained from cultures of UA159 were exposed to a challenge of 0.1 M glycine with constant stirring after overnight growth. Aliquots of 100 microliters of the UA159 suspension treated with 0.1 M glycine were sampled at 0, 15, 30, 60, and 90 minute time points, diluted and spiral plated for enumeration. Surviving colonies from the 0, 15, 30, 60, and 90 minute treated suspensions were enumerated to determine the percent survival of *S. mutans* compared to time 0. The results indicate that there is a 4 fold decrease in survival after 90 minutes of exposure to the low pH environment. Further implications for this study could link *S. mutans* acid survival with nicotine exposure. This could be correlated with the increased dental caries observed in smokers.

P45 “Click” Scaffolds for the Inhibition of *Porphyromonas gingivalis* and *Streptococcus gordonii* Biofilm Formation. C. LONER^{1*}, F. LUZZIO², D. DEMUTH (¹School of Dentistry; ²School of Arts & Sciences, University of Louisville)

Objective: Periodontitis and its systemic sequelae remain a major public health problem and developing a cost-efficient therapy will benefit healthcare worldwide. Adherence of *Porphyromonas gingivalis* to *Streptococcus gordonii* facilitates colonization of the oral cavity by *P. gingivalis* and contributes to the development of periodontal disease. It was previously shown that a synthetic peptide derived from the streptococcal protein SspB potentially inhibits this interaction and prevents formation of *P. gingivalis* biofilms. However, peptides are not ideal therapeutic agents. Consequently, our approach was to rationally-design small-molecule peptidomimetics that inhibit *P. gingivalis* adherence to *S. gordonii* that may represent viable therapeutic compounds. Methods: In terms of inhibitor design, a small molecule “click chemistry” strategy was employed whereby the azide-bearing partner constitutes a trisubstituted oxazole framework and the terminal acetylene partner constitutes a 1, 3-diaminotriazine framework. Results: The design, synthesis and chemistry of the coupling partners in both the acetylenic and azido series have been accomplished. Five azido compounds have been synthesized and one acetylenic compound. The backbone structure of the acetylenic compound was tested for inhibition of *P. gingivalis* adherence to streptococci and was shown to block adherence by 25% and 67% at concentrations of 25 μ M and 50 μ M, respectively. Conclusion: Bio-active small molecule peptidomimetics were synthesized that may represent therapeutic agents that could reduce *P. gingivalis* colonization of the oral cavity.

P46 Dynammin-GTPase Activity and Dephosphorylation by PTP-PEST Regulate Osteoblast Function. P. ELENISTE*, S. HUANG, A. BRUZZANITI (Indiana University School of Dentistry)

Bone mass is maintained by a coordinated balance between bone formation by osteoblasts (OBs) and bone resorption by osteoclasts. Our research is focused on understanding some of the key protein signals that are essential in OB and osteoclast function. Dynammin is a GTP-hydrolyzing enzyme (GTPase) that is expressed in OB and osteoclasts. Dynammin GTPase activity is regulated by the assembly of dynammin monomers and by phosphorylation at specific tyrosine residues. However, the phosphatase involved in the inactivation of dynammin, and the function of dynammin in OB is unknown. We recently reported that dynammin forms a protein complex with the protein tyrosine phosphatase PTP-PEST and Pyk2, and signaling from this complex is important for osteoclast function. We therefore examined if PTP-PEST regulates dynammin dephosphorylation and GTPase activity in OBs. We co-expressed dynammin and PTP-PEST and examined dynammin phosphorylation levels by immunoprecipitation, followed by Western blotting using a phospho-tyrosine specific antibody. In addition, we examined dynammin’s GTPase activity using an in vitro chemical assay. Experiments were performed in triplicate and replicated twice. We found that dynammin phosphorylation and GTPase activity were negatively regulated by PTP-PEST in a concentration and time-dependent manner. Interestingly, amino acid residues Y231 and Y597 were critical for dynammin dephosphorylation by PTP-PEST, and mutant dynammin Y231F and Y597F exhibited a 40-60% reduction in GTPase activity and phosphorylation levels, suggesting that Y231 and Y597 may be necessary for the assembly of dynammin monomers. To further examine the role of dynammin, OBs were treated with dynasore, a chemical inhibitor of dynammin, and we analyzed OB morphology, and migration. Dynasore-treated OBs exhibited a 70% decrease in actin stress fibers but a 40% increase in the number of focal adhesions. Consistent with the increase in actin-rich focal adhesions, we observed a 62% reduction in migration, compared to controls. Together, our studies suggest that dynammin GTPase activity is important for OB focal adhesions turnover, migration and bone formation by OBs.

P47 Three-Dimensional Airway Volumes and Most Constricted Areas in Children. E.J. AHN¹, K. KULA^{1*}, S. LIU¹, K.T. STEWART¹, G. ECKERT², S. HALUM², J.K. DILLEHAY³, F. ERASO⁴, A. GHONEIMA¹ (¹Indiana University School of Dentistry; ²Indiana University School of Medicine, ³Private Practice, Wichita KS, ⁴Private Practice, Indianapolis, IN)

The objectives of this retrospective study using cone beam computed tomography (CBCT) were to determine if there are differences in the volume of various airway segments and the most constricted area (MCA) of children with different dentoskeletal patterns. The initial CBCTs of 83 orthodontic patients (30 Angle's Class I; 26 Class II; and 27 Class III) were collected from a private orthodontic office. Following reliability studies, various parameters of the craniofacial complex, airway volume, and MCA were measured utilizing Dolphin 3D software. Comparisons among the three dental and the skeletal malocclusion classes were performed using one-way ANOVA and Fishers Protected Least Significant. Associations of the airway volumes and the MCA with other parameters were determined using correlation coefficients, accepting $p \leq 0.05$ as significant for all tests. Maxillary right sinus volume was the only airway segment showing significant difference among different dental classes. Maxillary sinus volume also correlated moderately with anterior facial height and mandibular length. No significant differences were found between the MCA and different dentoskeletal classifications. The only significant difference in airway parameters among the dentoskeletal classes was that the dental Class II subjects had greater right sinus volume than the other classes. Shorter anterior facial height or mandibular length could be indicators for decreased airway volume in children. **Funding:** IUSD Graduate Research Committee, IUPUI Three-Dimensional Imaging of the Craniofacial Complex Center, Jarabak Endowed Professorship

P48 Orthodontic Treatment Needs in Mexican-Mayan School Children. M. ESCOFFIE-RAMIREZ^{1*}, A.E. SOTO-ROJAS², K.T. STEWART², E.A. MARTINEZ-MIER², G.E. COLOME-RUIZ¹, J.R. HERRERA-ATOCHE¹ (¹School of Dentistry, Universidad Autonoma de Yucatan, Merida, Yucatan, Mexico; ²Indiana University School of Dentistry)

Objective: To assess the need for orthodontic treatment and degree of Mayan ancestry in school children 8-12 years old from a Mayan village in Yucatan, Mexico. Methods: A cross-sectional study was conducted in school children from the Mayan Village of Tahdziu in Yucatan Mexico. Three hundred and one, 8-12 year-old school children (10.33 ± 1.50 years old) were examined using the Dental Health Component (DHC) criteria of the Index of Orthodontic Treatment Need (IOTN). Mayan ancestry was evaluated through indicators; such as understanding and speaking Mayan and maternal and paternal last names. Counts and frequencies for the IOTN DHC, were obtained. The Mayan ancestry and DHC were then evaluated using Pearson's Chi-square tests. Results: 81.72% (n=246) of the school children had "low need for orthodontic treatment", 14.29% (n=43) had "moderate need for orthodontic treatment" and 3.99% (n=12) had "high need for orthodontic treatment". With respect to Mayan degree of ancestry, 50.50% (n=152) of the children had the highest degree followed by 39.87% (n=120) with a mild degree, while 9.63% (n=29) children were classified as non-Mayan. No statically significant association was found between the DHC and Mayan ancestry. Conclusion: No association was found between the Mayan ancestry and orthodontic treatment need in the school children from this village. Additionally, a large percentage of the children did not need orthodontic treatment.

P49 WITHDRAWN

P50 Orthodontic Treatment Needs in Mayan Adolescents in Yucatan, Mexico. M. ESCOFFIE-RAMIREZ¹, A. E. SOTO-ROJAS^{2*}, K.T. STEWART², E. A. MARTINEZ-MIER², J.R. HERRERA-ATOCHE¹, L.B. PEREZ-TRACONIS¹ (¹School of Dentistry, Universidad Autonoma de Yucatan, Merida, Yucatan, Mexico; ²Indiana University School of Dentistry)

Objective: This study assessed orthodontic treatment needs in a group of adolescents of varied Mayan ancestry in a village in Yucatan, Mexico. Methods: A cross-sectional study of 164 children, 12 to 17 years old (13.95 ± 1.06 years old), residents of Tahdziu, Yucatan were examined using the orthodontic treatment needs index (IOTN). The participant's degree of Mayan ancestry and principal language were assessed by determining if they spoke Mayan or Spanish and if their last names were of Mayan origin. Counts and frequencies for the IOTN Dental Health Component (DHC) and Aesthetic Component (AC) were obtained. The relationships between age, gender, and Mayan ancestry with the IOTN (DHC) and (AC) were evaluated using Mantel-Haenszel tests for ordered categorical data. Results: 56 (34%) adolescents were scored as low need for treatment by the IOTN DHC and 60 (36%) were scored moderate need. The highest score for orthodontic treatment needs was scored for 31 (19%) of the children. For the IOTN AC, 46 (28%) adolescents selected score 1, 74 (45%) score 2 and 32 (19%) score 3, higher scores were selected by 6 (4%) children. Higher subject age was associated with lower IOTN DHC scores ($p=0.03$). However, gender and ancestry were not associated with IOTN DHC. Neither age, gender, or ancestry was associated with the IOTN AC. There was a statistically significant association between the IOTN DHC and IOTN AC ($p=0.02$); however, this association was not very strong ($r^2 = 0.18$). No statistically significant differences were observed for adolescents with different Mayan ancestry levels; 38% of adolescents had the highest degree of Mayan ancestry, 49% mild degree and 13% were considered non-Mayan. Conclusion: There was a statistical association between the IOTN DHC and the AC components. The orthodontic needs of these Mayan adolescents were not high and they were not associated to Mayan Ancestry, age or gender.

P51 Comparison of Accuracy of Cast Duplication Using Thermoforming Material and Irreversible Hydrocolloid. K. PYCINSKA*, S. ISIKBAY, J.A. PLATT (Indiana University School of Dentistry).

The objective of this study was to compare the accuracy of dental cast duplication using two different thicknesses of thermoforming materials as well as irreversible hydrocolloid impression material. A master cast of a full dentition was cast out of pewter with reference points on the incisal cusps of the canines, lingual cusps of the second premolars, and mesio-lingual cusps of the second molars. Ten impressions of the model were taken using irreversible hydrocolloid in perforated stock trays, as well as with 2mm and 3mm thermoforming material using the Biostar Positive Pressure Thermal Forming machine all according to manufacturer's instructions. The impressions were poured using Type III Dental Buff Stone which was vacuum spatulated and allowed to set undisturbed for one hour prior to removal from the impression. Intra-arch distances from canine-canine, premolar-premolar, and molar-molar were measured three times on the master cast and duplicate casts using a measuring microscope (Nikon Measurescope UM2, Nikon, Tokyo, Japan) with a resolution of 1mm. Comparisons among the three impression methods for differences in each evaluated measurement were performed using one-way ANOVA. The 2mm thermoforming samples had statistically significantly lower measurements than the master cast for canines ($p=0.0243$), while the 3mm thermoforming samples had significantly lower measurements than the master cast for all three teeth ($p<0.0001$). The material-by-tooth interaction was statistically significant ($p=0.0002$). The 3mm thermoforming samples were significantly farther from the master cast than 2mm thermoforming samples ($p<0.0001$) and alginate samples ($p<0.0001$) for all tooth types. These results suggest that both alginate and 2mm thermoforming material can be used for cast duplication for orthodontic purposes, while the 3mm thermoforming material should not be.

P52 Personality as a Predictor of Willingness to Undergo Orthodontic Treatments.

V. HANSEN*¹, S. SCHRADER¹, S. LIU¹, B. VARGUS², J. DEAN¹, K.T. STEWART¹ (¹Indiana University School of Dentistry; ²Indiana University School of Liberal Arts)

Objective: To establish an association between patient personality and willingness to undergo various orthodontic treatments. Secondly, to validate a succinct questionnaire that may be used to evaluate potential patient adherence to orthodontic procedures. Materials and Methods: After obtaining IRB approval, a group of experts were assembled to identify and validate the items to be included in the survey. The expert group consisted of one pediatric dentist, seven orthodontists, a behavioral psychologist, and an expert in survey construction. Prior to the major study, a pilot study was conducted to determine the survey's construction validity, as well as its test-retest reliability. The final electronic survey contained 13 questions and three major sections: patient demographics, a modified BFI-10, and willingness to undergo treatment. The following inclusion criteria were established for the study: 1) between 12 & 16 years old and 2) willing to participate in the study. The exclusion criteria used in the study was as follows: 1) subjects with documented or discernible cognitive impairments, 2) a history of previous orthodontic treatment, 3) patients outside the set age range, 4) subjects unwilling to participate, and 5) subjects whose primary language was not English. The survey was administered to adolescents on an iPad via SurveyMonkey, a web-based surveying software. Results: The pilot study confirmed the validity of the study, with none of the subjects reporting any difficulty with completing or understanding the survey. The willingness to undergo orthodontic treatment section of the survey demonstrated fair to good test-retest reliability, with weighted kappa values ranging from .31-.81. One hundred and one subjects were recruited for the study, however, five subjects were excluded due to incomplete surveys (n=96). Statistical analysis from the main study revealed that agreeableness, neuroticism, extraversion, and conscientiousness were correlated with patient willingness to undergo certain orthodontic treatments (p=.05). The most significant of these personality types was agreeableness. Conclusion: Personality can be used in predicting a person's willingness to participate with orthodontic treatments. This survey is a valid instrument that can be used by dental professionals to predict a patient's willingness to undergo certain orthodontic treatments. Completion of a second study to confirm these findings would be prudent prior to the survey's widespread incorporation in orthodontic clinical settings.

P53 Orthodontic Correction of Lingually Displaced Mandibular Permanent Canines in Dogs.

E. McCREA*, K.T. STEWART (Indiana University School of Dentistry)

Background: Lingually displaced mandibular permanent canines is a common malocclusion in dogs. This malocclusion is caused by dental abnormalities, skeletal abnormalities, or both. There have been several reported treatment methods to correct this problem when it is of dental origin. In this case study, a dog presents with lingually displaced mandibular canines due to a combination of both dental and skeletal abnormalities. Orthodontics provides a non---invasive treatment alternative to extraction or pulp capping, both having many risks and complications. Objectives: The primary goal in correcting lingually displaced canines is to allow the animal to close its mouth fully without traumatizing the palate. The objective of this case study is to describe an orthodontic approach to correct the dental abnormality, lingually displaced mandibular canines, while also allowing the growth potential to resume and improve the underlying skeletal abnormality. Materials and Methods: A 7 ½ month old male Bernese Mountain Dog presented with a retrognathic mandible resulting in mandibular distocclusion. Due to this abnormal skeletal relationship, the mandibular permanent canines were displaced lingually, which created traumatic pits in the palate. An acrylic inclined bite plate was fabricated to open the bite, allow for normal growth to resume, and tip the mandibular canines buccally into a stable and non---traumatic occlusion. The bite plate was cemented to the maxillary canines so that the mandibular canines would hit the acrylic at the top of the incline, and be guided buccally as the bite closed. Results: After 22 weeks of treatment, the mandibular canines were successfully guided into a favorable position. The anterior overjet was reduced

from 12mm to 4mm. Discussion: The decrease in anterior overjet suggests mandibular growth and/or a more forward position of the lower jaw. In the original malocclusion, the mandibular canines were trapped in the palatal pits and the lower incisors were trapped posterior to the incisive papilla. It is hypothesized these factors were preventing the full growth potential and contributing to the skeletal discrepancy. The bite plate opened the bite, thus un---locking the lower jaw from this distal position, and allowed for normal growth to resume. In conclusion, acrylic inclined bite plates are an effective method for orthodontically correcting a dental abnormality in dogs. When treatment is initiated during peak growth, it is also possible to improve a skeletal abnormality.

P54 Inclusion of Second Molars and Outcomes of Orthodontic Treatment. K. HUNGATE*, H. KANG, S. LIU, K. KULA, K.T. STEWART (Indiana University School of Dentistry)

The purpose of this retrospective study was to evaluate orthodontic cases and determine whether a significant correlation exists between the case outcome measured using the Cast-Radiographic Examination (CRE) and the initial eruption status of the second molars, as well as the inclusion and/or timing of banding or bonding (b/b) of the second molars. This study reviewed an initial sample of 569 consecutively completed cases from a graduate orthodontic clinic. Inclusion criteria for the study included: 1) Cases completed between July 2006 and 2008, 2) Non-surgical cases, 3) Cases with complete pre-treatment/post-treatment records and 4) Cases with a minimum Discrepancy Index (DI) of 10. For cases meeting the specified criteria (n=209) the DI and CRE scores, as well as, information regarding the (b/b) of second molars were recorded in a randomized de-identified Excel spreadsheet. Descriptive statistics and multiple regression analysis were completed. Significance was established at 0.05. The average overall CRE score was 27.7 and the average second molar CRE scores was 10.2, 36.8% of the total CRE. No significant correlations were observed between overall CRE score and the (b/b) time of second molars, as well as the eruption status or inclusion of the second molars. Treatment time was significantly impacted by both the bonding time (P=0.0012) and DI (p=0.0016). Though the initial eruption status and the (b/b) timing of the second molars do not appear to affect overall CRE scores, clinicians should not treat second molars indiscriminately. Our results support previous studies that illustrate second molars account for approximately one-third of the overall CRE score. Therefore, an improvement in second molar CRE score would correspond to an improved total CRE score and improved orthodontic outcome.

P55 Basic Orthodontic Instruments: Identification and Uses in Clinical Orthodontics. B. CHAI*, K. KULA, K.T. STEWART, T. KULA (Indiana University School of Dentistry)

There are many types of instruments available for clinical orthodontics. The purpose of this interactive multimedia educational program is to educate orthodontic personnel such as residents and dental assistants, on the types and uses of basic orthodontic instruments. After completion of this program, the user should be able to identify the various instruments, their basic properties and uses in clinical orthodontic practice. The main emphasis of this multimedia program is visual presentation and user interaction. This multimedia program will incorporate features to help the user navigate through the identification and uses of orthodontic instruments. For example, “hot words” will be hyperlinked to pictures or videos that will feature certain instruments. Information can be accessed in a linear or branched pattern from the main menu. Quizzes will be available at the end of each section to assess and reinforce the user’s knowledge. After completion of the curriculum, the users can provide feedback on the program through an electronic survey. The multimedia program will be distributed as a *universal serial bus* flash drive to each orthodontic personnel prior to the commencement of their clinical training. For this multimedia program, 29 orthodontic instruments were selected and organized into five major kits based on their primary uses: exam kits, banding kits, bonding kits, wire insertion/change kits and

debanding/debonding kits. Pictures were taken with a Nikon D90 camera with macro lens. Videos were recorded with a Sony HD camera equipped with a Zeiss lens inside a Smith-Victor tent kit. All pictures and videos were then incorporated into Sum Total ToolBook 11 computer software for this multimedia program. Multimedia education can serve as a useful tool in the training of orthodontic personnel. In particular, asynchronous multimedia visual presentation and interaction enables users to be more engaged and independent in the learning process. Orthodontic residents and dental assistants can utilize this resource to gain familiarity with orthodontic instruments prior to their clinical training. Once users are equipped with the fundamental knowledge of these instruments, more emphasis can be placed on advancing and refining their skills in the orthodontic clinic.

P56 Systematic Review of Transposed Teeth. E. TAING-WATSON*, K.T. STEWART, S.LIU
(Indiana University School of Dentistry)

Background: The prevalence of dental transpositions has been reported in the literature to be 0.33%. Despite its rare occurrence, it is necessary to understand how to manage patients who present with this anomaly. Objective: The purpose of this systematic review is to examine the literature published on dental tooth transpositions, review treatment modalities, and provide recommendations for the clinical management of this dental anomaly. Materials and Methods: An electronic search of 2 databases (PubMed & Web of Science) was performed from 1950 to 2011. Articles falling into the following categories were excluded from this study: opinions/editorials, articles in non-peer reviewed journals, non-English papers, animal studies, cross sectional studies with no treatment rendered, and non-relevant studies. Five variables were collected from each of the qualifying articles: gender, patient age, teeth transposed, treatment rendered (extraction, maintain transposition, correct transposition), and treatment time. Results: The electronic databases were queried using the terms: “transposed teeth”, “transposed tooth”, and “transpositions”. The search produced an initial sample of over 200 hundred articles. After applying the exclusion criteria, 86 articles were reviewed by a single examiner for data extraction. Within the eligible articles, no clinical controlled trials identified. The majority of articles obtained were case reports. The reviewed case reports illustrate a shift in treatment management of transposed teeth. Prior to the mid 1990’s, the majority of cases were treated by maintaining the transposition. After the 1990’s, however, the treatment of choice was to correct the transposition orthodontically. Conclusions: After reviewing the literature, there is insufficient strength of evidence to provide substantiated treatment recommendation for orthodontic practitioners. More randomized control trials should be conducted to better guide practitioners in the orthodontic management of transposed teeth. The recent trend towards the orthodontic correction of tooth transpositions might be explained by advances in technology. With the advent of miniscrew implants and cone beam computed tomography(CBCT), clinicians now have enhanced diagnostic abilities and thus are better able to restore a patient back to a more natural occlusion.

P57 The Reliability and Reproducibility of Conventional, Digital and CT Created Cephalograms: A Comparative Study. A. GHONEIMA^{1,2*}, S. ALBARAKATI³, A. BAYSAL⁴, T. UYSAL⁴, AND K. KULA¹ (¹Indiana University School of Dentistry; ²Faculty of Dental Medicine, Al-Azhar University, Cairo, Egypt; ³College of Dentistry, King Saud University, Riyadh, Saudi Arabia; ⁴Faculty of Dentistry, Izmir Katip Celebi University, Izmir, Turkey)

The purpose of this retrospective radiographic study was to determine the reliability and reproducibility of skeletal and dental measurements of lateral cephalograms created from computed tomography (CT) scan compared to conventional and digital lateral cephalograms. CT and conventional lateral cephalograms of the same patients were obtained from the University archives. The lateral cephalometric radiographs of 30 patients were manually traced. The radiographs were then scanned and traced using Dolphin Imaging software version 11 (Dolphin Imaging, Chatsworth, CA). The CT created lateral cephalograms were also

traced using the same software. A total of 16 (10 angular and 6 linear) measurements were performed. Cephalometric measurements performed on conventional, digital and CT created cephalograms were compared statistically using repeated measures analysis of variance. Statistical significance was set at $p < 0.05$ except for the mandibular length which had a correlation of 0.82 for the CT created cephalogram. Five measurements (N-A-Pog, N-S, ANS-PNS, Co-ANS and Co-Gn) were found to be significantly different between the CT created and conventional cephalograms and three measurements (SNB, ANB, and /1-MP) were found to be significantly different between the CT created and digital cephalograms. The measurement differences between the conventional, digital and CT created cephalograms are statistically significant, but clinically acceptable. Funding: IUPUI Three-Dimensional Imaging of the Craniofacial Complex Center, Jarabak Endowed Professorship.

P58 An Internal Reference for CBCT Based Bone Mineral Density Measurement. S.I. GANS*, T.T. TAYLOR, A.H. KIM, E. JUNG, J. CHO, D.G. KIM (The Ohio State University College of Dentistry)

Objectives: The reliability of CBCT based bone mineralization measurements has not been fully evaluated. The absolute value of bone mineralization varies between different CBCT images. The objectives of this study were to find an internal reference region that has the least inter-CBCT image variance for a degree of bone mineralization (DBM) and how the internal reference is used to analyze a regional variation of oral DBM. Method: Sections of human mandible obtained from 7 individual cadavers (5 males and 2 females, 81.2 yrs) were scanned using cone beam computed tomography (CBCT) at the 200, 300 and 400 micron resolutions that are the same scanning range in clinic. Enamel and bone voxels in CBCT images were segmented from non-bone voxels. The alveolar bone (AB) region was digitally isolated within 1 mm outside root surface and the basal control bone (CB) was determined at 0.6 mm inside mandibular bone borders. The DBM histogram was obtained by calibrating a CT attenuation value of each bone voxel to a mineral density using known phantoms. Mean, standard deviation (SD), and coefficient of variation ($COV = SD/mean$) of DBM in each region were obtained. F-test for inter-specimen variances and paired t-tests for regional variations of the DBM parameters were performed. Results: The means of DBM in CB had the least inter-CBCT variance resulting in significant differences from those in enamel at 300 and 400 micron scans ($p < 0.02$). The SD and COV in AB were significant higher than those in CB independent of scanning resolutions ($p < 0.002$). Conclusion: The DBM in CB is likely used as an internal reference for comparisons of DBM. The higher variability (SD and COV) of DBM in AB than that in CB would result from active bone remodeling due to masticatory functional demand. The regional variations of DBM were consistently assessed at all scanning resolutions.

P59 Effects of Orthodontic Mini-Implant Diameter on Microdamage. E. CRUZ MARROQUIN^{1*}, S. LIU¹, J. SUN¹, S.B. BLANCHARD¹, A.E. SOTO-ROJAS¹, K.T. STEWART¹, M.R. ALLEN² (¹Indiana University School of Dentistry; ²Indiana University School of Medicine)

Microdamage reduces bone mechanical properties and thus could possibly contribute to implant failure. The objective of this study was to investigate whether the diameter of mini-implants (MI) affects microdamage generation and whether this differs between the mandible and maxilla due to their contrasting cortical thicknesses. Methods: Maxillary and mandibular quadrants of 5 dogs were randomly assigned to receive no intervention (control), pilot drilling only, or pilot drilling plus one of three diameters of MI: 1.4 (n=18), 1.6 (n=18), and 2.0 mm (n=18) immediately after sacrifice. Microdamage was assessed on basic fuchsin stained sections using epifluorescence microscopy. Results: No microdamage was found in the non-drilling controls. Pilot drilling produced only minimal microdamage in the maxilla but more microdamage in the mandible. There was significantly higher microdamage generated in the

mandible, compared to the maxilla. Conclusion: Insertion of MIs in the mandible produced higher microdamage than in the maxilla, which may explain that the higher MI failure rate in the mandible. Implant diameter did not affect overall microdamage burden in either jaw. Microdamage was mostly generated by pilot drilling through the cortex in the mandible, while microdamage in the maxilla was mainly produced when manual inserting MIs after pilot drilling.

P60 How to Prevent Tooth Rotation During Orthodontic Space Closure. D. WU*, J. CHEN, S. ISIKBAY, Z. XIA, K.T. STEWART (Indiana University School of Dentistry)

The objective of this study was to explore the ideal approach to prevent tooth rotation when using a power chain to close extraction space in orthodontic treatment. Method: A custom-made acrylic model was made with well-aligned teeth with bonded brackets. An extraction space was created distal to the lateral incisor and the model was mounted on an orthodontic force tester. The lateral incisor was attached to a load cell for quantifying the initial force and moments generated during space closure with 6 approaches. They were the combination of 2 power chain engagement (around the whole bracket or the wings adjacent to the space) and 3 ligation methods (no ligature tie, ligature tie around the whole bracket, or ligature tie the wing adjacent to the space). A 0.010" stainless steel (SS) wire was used for ligature tie. These tests were performed on 3 different size (0.016", 0.018", 0.016x0.022") SS archwires separately. The power chain was activated with a fixed length and connected between the lateral incisor and the canine to close the space. Six force and moment components were recorded for each combination. Each combination was tested ten times for assessing variations. One-way analysis of variance tests with Tukey HSD post-hoc paired comparisons were performed to compare the 6 combinations of power chain engagement and ligation methods on 3 SS archwires. Results: Initial force varied among 6 methods along the mesial-distal axis on 0.018" and 0.016x0.022" SS archwires. With all 3 wires, the rotation tendency was found the least when only using the power chain engaged on the wing adjacent to the space without ligature tie, followed by ligature tie overlaid with power chain only on the adjacent wing, power chain over the whole bracket, and ligature tie the whole bracket with power chain only engaged on the adjacent wing. The highest rotation tendency occurred when using power chain engaged on the whole bracket with ligature tie over the whole bracket or only the adjacent wing. Conclusion: To reduce rotational tendency using a power chain for orthodontic space closure, it is suggested to connect the power chain only to the adjacent wing to the extraction space. Supported by IUSD student research fellowship.

P61 Can Fluoride Prevent Genetically Predisposed Root Resorption in Tooth Movement? S. LIU*, J. SUN, M. FANNING, E.A. MARTINEZ-MIER, S. LI, K. KULA, K.T. STEWART (Indiana University School of Dentistry)

Objective: The purpose of this study was to determine whether systemic fluoride administration renders orthodontically treated teeth more resistant to root resorption in genetically susceptible mice. Method: 7-week-old, DBA/2J mice (n=24), genetically susceptible to root resorption, were randomly divided into 2 groups: 12 mice administered 100ppm [F⁻] fluoridated (NaF) water and 12 mice administered deionized (DI) water for 4 weeks. At 11 weeks of age, each animal experienced 4g of orthodontic force by a NiTi closed coil spring between the left maxillary first molar and incisors for 10 days. After sacrifice, the maxillae were scanned using micro-computed tomography and total tooth volume and density were digitally quantified using Mimics software. Wilcoxon signed rank tests were used to compare the total tooth volume and density between the treated and control teeth. Wilcoxon rank sum tests were used to compare the same measurements between fluoridated and DI water groups. Maxillary left first molars were extracted and analyzed for total tooth fluoride content. Result: All teeth that experienced orthodontic force displayed significant root resorption, but the teeth of animals that consumed fluoridated water did not demonstrate significantly less root resorption. The

maxillary first molars of the mice administered fluoridated water contained significantly higher amounts of fluoride than the molars of mice administered DI water. Conclusion: The evident genetic predilection to orthodontically-induced root resorption, specifically, a reduction in radiographic volume and density, cannot be overcome by systemic fluoride administration nor higher fluoride concentration in the teeth of genetically susceptible mice.

P62 Change of Loadings Delivered by Segmental T-Loops for Canine Retraction. Z. XIA¹, J. CHEN^{1,2}, S. LIU², F. JIANG¹, and R. VIECILLI³ (¹Indiana University-Purdue University Indianapolis; ²Indiana University School of Dentistry; ³New York University College of Dentistry)

Objectives: Segmental T-loops are used in maxillary canine retraction. The resulting orthodontic load-system on the canine is affected by multiple factors, such as interbracket distance (IBD) changes and tooth angulation. The load-system reduces as the canine moves. This study aims to experimentally quantify the load changes due to canine retraction. Methods: The load systems of two groups of 17 segmental TMA T-loops in six bilateral canine retraction patients were used in this study. Their values before and after each treatment interval were tested on the corresponding maxillary dental casts using a custom-made orthodontic force tester. Both groups had an initial average retraction force of 125 cN. The average initial anti-tipping moment of each group was 6.1 N-mm for controlled tipping and 7.7 N-mm for translation. The other moment and force components were kept minimum. The same spring was then mounted on the cast made after the treatment. The residual load system was measured. The pre- and post-treatment IBDs were recorded for calculating the amount of space closure. Results: The initial IBDs in this study range from 16.1 to 24.4 mm because of interpersonal difference or incremental tooth displacement. As IBDs decrease due to canine retraction, the averaged *Retraction Force Drop per IBD Decrease* is 38 cN/mm, a 30% drop per 1 mm IBD decrease ($P < 0.0001$); and the averaged *anti-tipping Moment Drop per IBD Decrease* is 0.8 N-mm/mm, ~12% drop per 1 mm IBD decrease ($P = 0.0151$). The results indicate that the moment is less sensitive to IBD decrease than the force. Consequently, the average *Moment-to-Force (M:F) Ratio Increase per IBD Decrease* is 1.9 mm/mm ($P = 0.0001$). Conclusions: In canine retraction, the retraction force decreases percentagewise more than the anti-tipping moment, which results in the M:F ratio increase. The initial M:F ratios need to be lower than ideal to reach the expected values. This research was supported by NIDCR R01-DE-018668.

P63 Myths and Truths of Oral Piercings T.COUCH^{1*}, J. HUNLEY¹, C. RILEY¹, P. CLARK² (¹Scottsburg Middle School; ²Indiana University School of Dentistry)

The objective of the research was to discover the effects of piercings on oral health. We used various internet sites, including the ADA site, for our research. Piercings can cause chipped teeth and tooth fractures. Nerve damage, gum disease, and bone loss are all possible outcomes from the jewelry damaging the tongue, teeth, and gums. In addition, bacteria from the mouth can enter the body through the pierced openings causing a variety of illnesses. Although popular, especially with young people, oral piercings are harmful to both oral and overall health. Supported by the Indiana University School of Dentistry.

3:30 p.m. to 4:30 p.m.

P64 Are the Diets of Children Who Attend the Dentist Regularly Healthier Than Those Who Seldom Visit the Dentist? K. CZARKOWSKI*, J.E. KOWOLIK (Indiana University School of Dentistry)

This study reviewed and compared the dietary plans of children who are under the care of their parents or caregivers when at home and reviewed whether children who see the dentist regularly have a healthier diet than those who seldom visit. This study examined the dietary habits of children who are seen in the pediatric dental clinic from ages 1-18. Survey questionnaires were distributed to parents and caregivers while they waited for their child to be treated in the pediatric dental clinic at Indiana University School of Dentistry. The data gathered from the questionnaires addressed the types of food consumed by children while in the care of parents or caregivers at home, as well as any type of oral hygiene education provided by parents and dentists to children regarding diet and hygiene. Of the patients who completed the survey, the majority were seen for their semi-annual check-up with the remainder of patients being seen for restorative and preventative care. Parents commonly gave their children crackers, fruits, cookies and vegetables with mainly cariogenic juices and water throughout the day. All parents and caregivers stated they educated their children about oral hygiene and tooth brushing. Due to the small population size the results could not give a clear determination of whether the diets of children who attend the dentist regularly are healthier than those who seldom visit a dentist. This research was supported by the Department of Pediatric Dentistry at Indiana University School of Dentistry.

P65 Pediatric Dental Referral: Assessing the Referral Environment. K. LUDWIG*, J.E. KOWOLIK (Indiana University School of Dentistry).

The objective of this study is to evaluate the current referral environment between pediatricians and dentists to assess pediatricians' ability to refer children for their first dental appointment. Members of the Indiana chapter of the American Association of Pediatricians (INAAP) were surveyed using a web-based questionnaire exploring referral methodology, preferences of attributes of dentists and resources, and a self-report of practice demographics. A second, phone-based survey of licensed Indiana dentists examined dentists' willingness to share pertinent referral information, their current relationship with local pediatricians, and their practice demographics. Responses were summarized using frequencies and percentages, and comparisons were made using chi-square tests. INAAP members (n=44), show 48.8% of participants make referrals for over 80% of their patients with 90% giving specific contact information when making referrals. Half of respondents believed their referrals resulted in regular dental care greater than 60% of the time. The greatest barriers to referral were reported as patients insured with Medicaid (50%), young patient age (33%), and a lack of information about available dentists (31%). Surveyed Indiana dentists (n=93) had a relationship with pediatricians (48%), most commonly saw children by 3 years of age, and reported accepting those insured with Medicaid (47%). Over 90% would provide pertinent referral information to pediatricians to aid in making referrals. Pediatric dentists are twice as likely compared to general dentists to know pediatricians in their communities (p=0.0110) and receive referral patients from pediatricians (p=0.0004). Current barriers to dental referral may be reduced with greater communication between general dentists and pediatricians; however, due to some dentists' lack of treating young patients and those insured with Medicaid, pediatricians should consider providing anticipatory guidance and preventative oral health care until a dental home is established.

P66 Metronidazole-Containing Devices: Effect on the Oxidative Burst of Human Neutrophils.
A.C. STARR*, N.K. AL-SHIBANI, N. LABBAN, M.J. KOWOLIK, M.C. BOTTINO (Indiana University School of Dentistry)

Background: The design of drug (metronidazole, MET)-containing devices have recently shown to be able of delivering locally, in the periodontal pocket, effective dosages capable of eliminate/prevent pathogens, without the side-effects associated with the oral intake of antimicrobials. The aim of this study was to evaluate the effect on the oxidative activity of neutrophils by chemiluminescence (CL) of MET-containing biodegradable devices. Methods: Polymer-based biodegradable samples consisting of poly(lactide acid) and type-B gelatin (PLA:GEL) were fabricated via electrospinning containing two distinct MET amounts (5 and 25 wt.%). Electrospun samples consisting of PLA:GEL only was processed to serve as control. Scanning electron microscopy (SEM) was used to analyze fiber morphology and morphological structure, while tensile testing measured the mechanical properties. Neutrophils were separated from six buffy coats obtained from freshly collected human whole blood (IRB#1201007709) to be used in the evaluation of inflammatory cell oxidative activity (ROS) using the luminol-dependent chemiluminescence assays (CL). Neutrophil activation was recorded as the total integrated energy output. Comparisons between the groups were performed using analysis of variance (ANOVA) with a term for group and a random effect for experimental run. To satisfy the ANOVA assumptions the analyses were conducted on the ranks of the data. Results: SEM imaging revealed a structure composed randomly oriented non-woven fibers for all groups. A significant increase in fiber diameter was observed in the drug-containing membranes (5wt.%MET-1346±348nm and 25wt.%MET-1647±325nm) when compared to the control (686±222 nm). In terms of mechanical properties, MET addition yielded scaffolds with greater tensile strength than the control. There was no significant statistical difference in the ROS between (5 and 25 wt.% MET) and the membrane control. The membrane control was significantly different from the negative control ($p < 0.05$). Conclusion: Based on CL data, 5 and 25 wt.% MET do not differ in their ROS production.

P67 Oxidative Burst of Human Neutrophils Induced by Doxycycline-Containing Devices.
H. AHDAB*, N.K. AL-SHIBANI, N. LABBAN, M.J. KOWOLIK, M.C. BOTTINO (Indiana University School of Dentistry)

Background: Clinically, the oral administration of antibiotics such as doxycycline (DOX) as an adjunctive treatment for periodontal diseases has been helpful in reducing and/or eliminating the presence of pathogens in the gingival fluid and periodontal pocket. The purpose of this study was to investigate the effect of DOX-containing polymer-based electrospun devices on the oxidative activity of neutrophils by chemiluminescence (CL). Materials and Methods: Electrospun samples were fabricated after a careful optimization process from solutions of poly(lactic acid) and type-B gelatin dissolved in hexafluoro-2-propanol containing doxycycline-DOX at different concentrations (5 and 25 wt.%). Samples without DOX were processed as controls. Fiber morphology/diameter was investigated using scanning electron microscopy (SEM). Mechanical properties of the membranes were assessed by tensile testing. For the CL assay, neutrophils were separated from buffy coats (n=6) obtained from whole blood of healthy adults (IRB#1201007709) and used in the evaluation of inflammatory cell oxidative activity (ROS). Neutrophil activation was recorded as the total integrated energy output. Group comparisons were conducted using analysis of variance (ANOVA) with a term for group and a random effect for experimental run. Analyses were performed on the ranks of the data in order to satisfy the ANOVA assumptions. Results: SEM imaging confirmed the fabrication of defect-free electrospun samples formed by randomly oriented non-woven fibers. Based on the fiber diameter data, DOX-incorporation seemed not to significantly increase fiber diameter (5wt.%-880±339 nm and 25wt.%-762±228nm) when compared to the control (PLA:GEL-686±222 nm). However, the incorporation of DOX led to an enhancement in the tensile strength. Regarding the ROS, 5wt.% DOX was not significantly different from the control ($p=0.07$), but 25wt.%

DOX revealed a significantly lower ($p < 0.05$) ROS than the control. Conclusion: 25wt.% DOX electrospun drug-delivery devices presented an unexpectedly lower ROS production than 5wt.% DOX.

P68 Electrospun Drug-Delivery Device for the Treatment of Periodontal Disease.

J.G. CORCORAN*, B. LI, K.S. GREGSON, R.L. GREGORY, M.C. BOTTINO (Indiana University School of Dentistry)

Background: Local drug delivery devices have shown potential as an alternate treatment as opposed to the use of systemic antimicrobials in the treatment of periodontitis. In this study, we report the fabrication/characterization of polymer-based electrospun fibrous devices incorporated with metronidazole benzoate (MET) while also determining their antibacterial potential and cytotoxicity against human gingival fibroblasts (HGFs). Materials and Methods: The solution used to fabricate the devices contained poly(DL-lactide-co-glycolide) (PLGA) and a natural polymer (Gelatin, GEL) in a 4:2 mass ratio. PLGA:GEL solutions containing two concentrations of MET (5 and 25 wt.%, relative to the total polymer weight) were also prepared. MET-containing fibrous mats were collected on a rotating mandrel by co-electrospinning. Fibrous mats containing no MET were used as a control. Characterization of fiber morphology was performed using scanning electron microscopy (SEM). FTIR spectroscopy, drug release experiments, and uniaxial tensile testing were also performed. The antibacterial potential of the devices was tested against *Streptococcus mutans* and *Porphyromonas gingivalis*. Results: SEM images of the electrospun mats revealed that they generally exhibited open porosity and interconnected structures formed by the random orientation of the non-woven fibers which mostly had submicron diameters. FTIR analysis revealed strong peaks corresponding to PLGA, GEL, and MET. The drug release experiment showed that the peak release occurred at 24 hours and 1 week for 5 and 25 wt.% MET mats, respectively. The 25 wt.% MET mats demonstrated the greatest (~ 3.5 MPa) tensile strength. The *in-vitro* cell viability assay revealed that only the 25 wt.% MET mats showed a statistically significant cytotoxicity. Antibacterial studies showed that both MET concentrations were effective at preventing biofilm formation and planktonic growth. Conclusion: Based upon their biocompatibility and antibacterial properties, the electrospun devices formed in this study show clinical promise for an effective local drug delivery system to treat periodontal disease.

P69 Distinct Salivary-Biomarkers Profile in Health Versus Chronic-Periodontitis and Treatment Effects. S. PRAKASAM*, M. SRINIVASAN (Indiana University School of Dentistry)

Saliva has potential to diagnose chronic periodontitis (CP). Changes in tissue-expression of pattern-recognition-receptors (PRRs), which recognize periodontal-pathogens, correlate with CP. It follows that PRRs-expression in nucleated-cells shed in saliva (NCs) and soluble-PRRs may differentiate CP from health. Additionally, cytokines in GCF correlate with worsening CP, which may-be reflected in saliva. One significant test for biomarkers is changes in response to treatment. The aims of this study are to compare the salivary-biomarker profile of CP with that of healthy individuals and to study treatment effects. Unstimulated-whole-saliva (UWS) collection/recording of routine clinical/periodontal-parameters was done for two groups healthy H-group (minimal CAL & clinical-inflammation) versus {CP-group at 3 different time points- before, 1 week and 6 weeks after SRP ($\geq 30\%$ sites with ≥ 4 mm clinical loss of attachment (CAL)) of systemically-healthy individuals (16-per-group), at defined time points before and after treatment (Scaling and root planing – SRP). NCs & clarified saliva (CS) were separated from UWS. Messenger RNA was extracted from NCs and TLR-2 expression was quantitated through real-time-PCR. CS depleted of immunoglobulin & amylase (prevent large molecule interferences) and diluted to $1\mu\text{g/ml}$ of salivary-protein in PBS (normalize for variations in liquid volume) was used to quantify biomarkers through ELISA. Significance between H and CP-group biomarkers was determined through Mann-

Whitney-'U'-Test. One-tailed-paired-'T'-tests determined significance of SRP-mediated salivary-biomarker changes in CP. Statistically significant differences were noted for clinical-profiles of H and CP-groups and for changes after SRP within CP-group. Distinct salivary biomarker profiles were noted between health and CP as well as before and after treatment in CP. Briefly, salivary sTLR-2, IL-17, & IL-10, were significantly higher, and sCD14, IL-6, IL-4 & TLR-2 mRNA were significantly lower in H (compared to CP). In CP, salivary sTLR-2 & IL10 increased significantly at 1 & 6 weeks after SRP whilst IL-4 decreased significantly at 6 weeks. Salivary-biomarkers profiles are distinct between health and CP as well as before and after SRP treatment. sTLR-2, IL-10 and IL-4 may serve as short-term biomarkers for monitoring response to SRP. sCD14, TLR2-mRNA and other cytokines need exploration as long-term-response biomarkers. Depletion of amylase and immunoglobulin and normalization for liquid-volume may be important steps in biomarkers quantification.

P70 **Alternation of Alveolar Bone Mineral Distribution in Periodontitis Patients.** V. ARIAIL*, H.H. CHIEN, E. JUNG, M.J. LEE, B.C. TEE, D.G. KIM (The Ohio State University College of Dentistry)

Objectives: Periodontitis is characterized by loss of alveolar bone (AB) surrounding teeth. As such, active bone remodeling likely involves in the bone loss process. It was hypothesized that degree of bone mineralization (DBM) at AB region will be altered resulting from the active remodeling associated with periodontitis. The objective of this study was to examine if the DBM distribution is different between healthy and periodontitis AB regions in patients. Methods: After approval of IRB, clinical cone-beam computed tomography (CBCT) images obtained from 9 periodontitis patients (2 males and 7 females, mean 62.08 yrs) were identified from 350 patient CBCT database. *Periodontitis was defined* as clinical *attachment loss* greater than 3 mm around teeth. Bone voxels in CBCT images were segmented from non-bone voxels using a heuristic algorithm. The 3D AB region surrounding teeth was digitally isolated within 1 mm outside root surface. Three groups of AB region were identified including normal control and disease sub-regions of AB at the same disease tooth (DC and DD, respectively), and normal control AB region at other healthy tooth (CC). The DBM histogram was obtained by calibrating a CT attenuation value of each bone voxel to a mineral density using known phantoms. Mean, standard deviation (SD), and coefficient of variation (COV=SD/mean) of DBM were obtained. Paired t-tests were used for comparison. Results: Mean of DBM between groups was not significantly different (1922 (DC), 1966 (DD), and 1939 (CC) mg/cm³, p>0.28). However, variability (SD and COV) of DBM was significantly different between DC and DD (p<0.001) while those between DC and CC were not different (p>0.77). Conclusion: The DBM distribution of AB was altered by periodontitis. This finding suggested that clinical CBCT based DBM analysis can help understand how AB properties change in the progress of periodontal disease and improve diagnosis of periodontitis in patients.

P71 **Fluoride Content of Stream, Well, and Bottled Water in Kenya.** J.R. EMHARDT^{1*}, E.A. MARTINEZ-MIER¹, P. CHANDRAPPA¹, K. YODER¹, B. OLIVER² (¹Indiana University School of Dentistry; ²Moi University School of Dentistry, Eldoret, Kenya)

The objective of this study was to compare the fluoride content of water samples obtained from streams, wells, and commercially available bottled waters in rural Kenyan villages near Eldoret, Kenya. Due to Kenya's unique climate, geology and lack of a universal water distribution system, Kenyan villagers must consume water from unregulated water reportedly high in fluoride concentration. 25 samples each were collected from wells and streams. 12 commercially available bottle waters were also purchased to determine fluoride concentration. They are being analyzed for fluoride and the results plotted on a map of the area. Fluoride analyses are being conducted directly under a fluoride specific electrode using a pH/ISE meter following standardized procedures. Preliminary stream fluoride concentration results for ten

samples analyzed to date show a mean of 0.40 ppm with a range of 0.14 - 0.85 ppm, while preliminary well fluoride concentration results show a mean of 0.41 ppm with a range of 0.09 - 1.48 ppm. Bottled water analysis showed a concentration of .26 ppm, (while the label on the bottle declared a concentration of 0.46). Preliminary results showed no statistically significant differences, but large variations within the same type of water source. There are large variations in different water sources in the communities near Eldoret in Kenya, with some of them having concentrations of fluoride higher than the optimally recommended.

P72 Current Attitudes Toward Magadi, a High-Fluoride Content Trona, in Eldoret, Kenya.

J.A. NEESE^{1*}, K. YODER¹, O. WATTA² (¹Indiana University School of Dentistry, ²Moi University School of Dentistry, Eldoret, Kenya)

The purpose of this study is to find out current attitudes toward Magadi, a high-fluoride trona, in Eldoret, Kenya. Not only is fluoride ingestion in excess amounts detrimental to the health of residents of some geographic areas in Kenya but to communities throughout the world. Food cooked with high fluoride containing Magadi results in a higher fluoride concentration of the cooked food (Yoder).

This study will investigate the current use of the food additive magadi, a high-fluoride trona, by residents of Eldoret, Kenya, as well as societal perceptions involved in its use. A combination of written and oral surveys will be administered and collected in order to determine the how and why the local population is using magadi. Preliminary data from the surveys acquired between June 2011 and October 2011 is as follows: In total, 61 surveys were collected by Ms. Neese and Mr. Watta. 30 survey respondents were male and 31 were female. Thirty-nine surveys were collected by Mr. Watta (18 of the respondents were male and 21 were female). Twenty-two surveys were collected by Ms. Neese (12 of the respondents were male and 10 were female). The average male respondent age was 40.53. The average female respondent age 37.61. The overall average age of the respondents was 39.05. The respondents were asked how many people live in your house, including themselves. The survey results yielded that overall an average of 4.39 people lived the household. 32 of the respondents reported that they had children under the age of 10 who ate food cooked with Magadi. The other 29 respondents responded to the question with "No" for one of two reasons. First, they no longer have children under the age of 10 in their household (22 respondents) and secondly, if they did have children under the age of 10 in the household, they did not feed the child food cooked with Magadi (7 respondents). In conclusion, the preliminary data proves that Magadi is a well-known substance in the Great Rift Valley. The majority of the respondents feed their children, who were under the age of 10 years old, food cooked with Magadi. There were only 7 respondents of the total 61 who had children under the age of 10, whom did no consume food cooked with Magadi. Analysis of the surveys along with the Magadi samples will lend further results to support the 3 hypothesis.

P73 Evaluating Need for Dental Care in Indiana Domestic Violence Shelters. T.J. KIMMEL^{1*}, K. YODER¹, G. ECKERT² (¹Indiana University School of Dentistry; ²Indiana University School of Medicine)

This survey aimed to identify the prevalence of dental trauma in victims of domestic violence presenting to domestic violence shelters in the state of Indiana, as well as the confidence of shelter staff in identifying dental trauma and making referrals to dentists or programs that can be of assistance. A paper survey was mailed to the 77 domestic violence shelters in Indiana asking the shelter directors to provide the number of clients their shelters serve, how many clients present with dental trauma, how many staff members the shelters employ, and how confident staff members are in identifying dental trauma and making referrals to dentists or programs that can be of assistance. A total of 29 surveys were returned. Survey responses were summarized using frequencies and percentages. Associations of the shelter location, the number of employees, and the number of individuals served at the shelter per month with the other survey items were analyzed using Mantel-Haenszel tests with ordered categorical responses. Results

of the statistical analysis showed the average number of clients presenting with dental trauma to domestic violence shelters to be 6 in a given year with a minimum of 0 and a maximum of 30. The majority of these individuals expressed to shelter staff a desire to seek dental care. The majority of shelter staff indicated confidence in making referrals for these clients to dentists or programs that can be of assistance. If a shelter had not made a referral, the most common reason was because the staff was not familiar with dentists or programs that were available to provide assistance. Rural shelters reported this unfamiliarity more often than did suburban/urban shelters ($p < 0.05$). Also, the more staff members a shelter employed and the more clients served by the shelter the more likely the shelter staff were to be familiar with programs/dentists to assist their clients ($p < 0.05$). The results suggest that individuals do present to domestic violence shelters seeking care for their dental trauma and the shelter staff are (and feel confident in) making referrals to dentists/programs. This is especially true for suburban/urban shelters that employ a larger staff size and serve a greater client base. Supported by a grant from the Indiana University School of Dentistry Student Research Fund.

P74 Drug-Containing Electrospun Scaffolds for Endodontic Revascularization. T. KAMP*, G. YASSEN, J.A. PLATT, K.J. SPOLNIK, M.C. BOTTINO (Indiana University School of Dentistry).

Background: Endodontic regeneration has been suggested as a treatment for necrotic immature teeth. Disinfection for the current endodontic regeneration procedure is typically achieved using antibiotic paste that is inserted into the canal. Unfortunately, the antibiotic paste may lack structural rigidity and may have very limited time-release capabilities, which are critical in eliminating persistent bacteria in the canal. The objective for this study was to fabricate and characterize polydioxanone-based electrospun membranes containing metronidazole/MET and ciprofloxacin/CIP) and to investigate their structural, morphological, and chemical properties. Materials and Methods: Polydioxanone/PDS was dissolved in hexafluoropropanol. Metronidazole or ciprofloxacin were mixed with PDS solution at 5% and 25 wt.% before electrospinning. Pure PDS solution was electrospun for use as a control. Scanning electron microscopy (SEM), microtensile testing and Fourier-transform infrared spectroscopy (FTIR) were used to assess membrane morphology, mechanical properties and chemical structure, respectively. Degradation studies were performed by immersing samples in Phosphate Buffered Saline/PBS and measuring the scaffolds mass loss at set time intervals. One-way ANOVAs followed by Tukey's test were used for statistical analyses. A 5% value was considered significant. Results: SEM imaging revealed a submicron fibrous morphology and a porous, intertwined network. FTIR confirmed the presence of characteristic peaks for PDS and the incorporated drugs. The tensile strength values of the dry control scaffold were significantly higher than all other dry scaffolds. The tensile values of hydrated 25wt.%CIP scaffold were significantly lower than all other groups. Furthermore, no significant difference was observed between all other hydrated scaffolds. The fiber diameter of the control and 5wt.%MET scaffolds were significantly larger than all other scaffolds. Conclusion: Results indicate that the addition of MET and CIP antibiotic at various concentrations affect the morphology and the mechanical properties of the suggested scaffold. Mechanically strong drug-containing scaffolds were fabricated. Assessment of cytocompatibility/proliferation issues are currently being pursued.

P75 Mechano-Biological Characterization of Electrospun Composite Scaffold for Regenerative Endodontics. G. YASSEN*, N. LABBAN, J.A. PLATT, L.J. WINDSOR, K.J. SPOLNIK, M.C. BOTTINO (Indiana University School of Dentistry)

Background: Pulp regeneration has been shown to occur in necrotic immature teeth after a procedure involving root canal disinfection and the formation of a natural fibrin-based scaffold. However, the outcome of this technique is unpredictable due to the uncontrolled characteristics of the fibrin clot and the possible toxic effect of the antibiotic pastes used for root canal disinfection. Objectives: to fabricate a biodegradable electrospun composite scaffold incorporated with aluminosilicate nanotubes (HNTs) and to investigate the effect of HNTs incorporation on morphological, mechanical, and biological properties. Material and Methods: Polydioxanone (PDSII) was dissolved in 1,1,1,3,3,3-Hexafluoro-2-propanol. HNTs were incorporated at various concentrations (0.5, 1, 3, 5, and 10wt.%) in the PDS solutions. The solutions were homogenized, sonicated, and electrospun to obtain the scaffolds. PDSII solution without HNTs was also electrospun. Scanning electron microscopy (SEM) and microtensile testing were conducted to characterize fibers diameter and mechanical properties, respectively. Furthermore, water-soluble tetrazolium-1 (WST-1) assay was used to investigate the proliferation of human derived dental pulp cells (IRB#1201007710) seeded on the scaffolds. One-way ANOVAs followed by Tukey's multiple comparisons were used for statistical analyses ($\alpha=0.05$). Results: Microtensile values for dry scaffolds were significantly higher for control and 0.5wt.%HNTs than for all other groups. Fiber diameter of 10wt.%HNTs scaffold was significantly greater than all other groups, and the 1wt.%HNTs scaffold fiber diameter was significantly larger than all remaining groups. WST-1 value was significantly lower for the control group (pulp cells without scaffold) compared to all other groups. However, no statistically significant difference in WST-1 values was detected among the groups (i.e., PDS and PDS/HNTs). Conclusion: The suggested electrospun composite fibrous scaffold offered a significant improvement in cell proliferation. HNTs incorporation affected the morphological and mechanical properties of suggested scaffold. Further optimization studies should be performed in order to improve the mechanical properties of the scaffold.

P76 Antimicrobial Properties of a Metronidazole-Containing Electrospun Polydioxanone(PDS) Scaffold. J.K. JEPPSON, Y. EHRLICH, M.C. BOTTINO, M.M. VAIL, K.J. SPOLNIK, D. JENKS*, R.L. GREGORY (Indiana University School of Dentistry)

Endodontic treatment of the infected immature tooth has undergone a dramatic change. Conventional endodontic treatment can control infection, but root development usually remains impaired. A novel regenerative endodontic procedure- the revascularization method can now control the infection and enable such teeth to continue root development. This is done by creating a fibrin-matrix scaffold in the antibiotic treated root canal space(RCS). Dental stem cells and growth factors have been able to continue root development in such an environment. The fibrin-matrix scaffold is dependent on the induction of a blood clot into the RCS and this cannot always be predictably induced. PDS is a biocompatible material that can be electrospun to provide a matrix for cells and growth factors and perhaps improve on the blood clot induced fibrin scaffold by incorporating metronidazole as an adjuvant antimicrobial. A metronidazole containing electrospun PDS scaffold was examined *in vitro* using a turbidimetric test, the modified direct contact test. This scaffold significantly inhibited growth of an anaerobic primary endodontic pathogen *Porphyromonas gingivalis*. This scaffold may improve the treatment of the infected immature tooth by providing a designed matrix for root regeneration while serving simultaneously as an antibiotic drug delivery device to disinfect the RCS.

P77 Salivary Biomarkers for Type-2 Diabetes Mellitus Identified by Bioinformatics Analysis. M. PRADHAN¹, M. SRINIVASAN², M.J. PALAKAL¹ (¹Indiana University-Purdue University Indianapolis; ²Indiana University School of Dentistry)

The American Diabetes Association estimates that over 23 million adults in the US have diabetes; nearly 95% develop type 2 diabetes mellitus (T2DM). Dysregulation of many biological pathways precedes the development of overt T2DM characterized by chronic hyperglycemia and reduced b-cell effectiveness. Improvement of risk prediction for T2DM is crucial for identifying high-risk individuals who could benefit from specific preventive measures. Targeted and non-targeted approaches in cross-sectional studies have indicated that genetic, proteomic and metabolite profiles differ between patients with T2DM and controls. For example a panel of six proteins including adiponectin, C-reactive protein, ferritin, interleukin-2 receptor A, glucose, and insulin has been suggested as strong predictors of an individual's 5-year risk of developing T2DM. The human salivary proteome database consist over 2290 proteins as opposed to 2698 plasma proteins. The non-invasive, painless collection and the feasibility of collecting several times a day to provide reliable assessments of diurnal fluctuations are significant advantages of whole saliva as a bio-specimen for monitoring T2DM. The overall goal of this project is to identify a panel of biomarkers in saliva by integrating literature mining and systems biology followed by validation in clinical samples. Initial approach consists of computer-assisted data mining that involves information retrieval or identifying relevant manuscripts, entity recognition of biological entities such as genes, proteins, metabolites and chemical compounds within publications and information extraction of specific facts from published literature. We have previously developed a user-centric bioinformatics research tool, called BioMap that provides a customized, adaptive view of the information and knowledge space. Using specific bait list encompassing pathophysiology of T2DM, serum and salivary proteome, we identified a network centered on an endogenous ligand for growth hormone, ghrelin that has been also linked to obesity, commonly associated with T2DM. T2DM has been associated with reduced serum ghrelin. Importantly the reduction has been correlated with serum glucose and insulin levels. In addition to ghrelin, the network also identified other proteins of the lipid metabolism that are recognized as potential serological markers of T2DM and measurable in saliva. In conclusion, bioinformatics analyses suggest that a panel of salivary proteins could serve as indicators of T2DM. Prospective assessment of clinical samples will be performed for validation.

P78 The Rho-GEF Kalirin Regulates Bone Length in Female Mice. N. SHAH*, S. HUANG, P. ELENISTE, A. BRUZZANITI (Indiana University School of Dentistry)

During growth, bone remodeling results in the progressive lengthening of bones and an increase in bone mass, until peak bone mass is reached. Kalirin is a novel GTP-exchange factor protein and other studies from our laboratory recently revealed that deletion of the *kalirin* gene in mice which leads to loss of Kalirin in all tissues (Kal-KO) leads to a 40% decrease in the bone mass of female mice at 14 weeks of age, compared to a 20% decrease in male mice. In this study, we examined the length of bones from wild-type (WT) and Kal-KO mice to determine the potential role of kalirin on longitudinal bone growth. We collected tibia from WT and Kal-KO female and male mice at 14 weeks of age, removed associated muscle tissue and then used a digital caliper to measure bone length. The average length \pm SD was recorded and a student t-test was performed. The tibia from female WT and Kal-KO mice were found to be 18.04 ± 1.04 mm (n=9) and 16.99 ± 1.06 mm (n=16) in length, respectively. The tibia from male WT and Kal-KO mice had an average length of 18.17 ± 0.53 mm (n=15) and 17.79 ± 0.70 mm (n=16), respectively. These studies reveal that tibia of female WT mice are significantly shorter than tibia from female Kal-KO mice (p=0.013). In contrast, the tibia of male Kal-KO mice are not significantly shorter than the WT mice (p=0.052), although they approached statistical significance. These studies suggest that Kalirin is involved in regulating bone length in female mice, suggesting it may play a role in the development of the skeleton during growth.

P79 The Effects of Nicotine and Cigarette Smoke Condensate on Human Endothelial Cells.

K. DELACRUZ*, E. ALLAM, J. SUN, L.J. WINDSOR (Indiana University School of Dentistry)

Past research has indicated that nicotine, the major addictive constituent in cigarette smoke, is directly related to the effects of smoking on the cardiovascular system such as the development of arterial diseases. The lining of vascular blood vessels is composed of endothelial cells, which are directly involved in homeostatic functions of the cardiovascular system. This study was performed to assess the effects of nicotine and cigarette smoke condensate (CSC) on the cell proliferation, viability, and cytokine/growth factor expression of human endothelial cells. Human umbilical vein endothelial cells (HUVECs) were cultured in Endothelial Basal Medium-2 supplemented with serum and seeded in 6-well plates. Each well was then exposed to nicotine or CSC (0-800 µg/mL). Endothelial cell proliferation and cytotoxicity were measured by the water-soluble tetrazolium-1 (WST-1) assays and lactate dehydrogenase (LDH) assays, respectively. WST-1 results indicated that cell proliferation decreased at 400 and 800 µg/mL nicotine in comparison to the control. Results of the LDH assays showed increasing cytotoxicity at 200, 400, and 800 µg/mL of nicotine and 200 and 400 µg/mL of CSC when compared to the control. According to the human cytokine antibody array, both nicotine and CSC altered various cytokine/growth factor expression levels. Results of this study indicate that nicotine and CSC potentially contribute to negative effects on the cardiovascular system.

P80 Interactions of Human Endothelial Cells with *Streptococcus mutans*. J. RODENBECK*,

R.L. GREGORY, N.K. AL-SHIBANI, L.J. WINDSOR (Indiana University School of Dentistry)

Streptococcus mutans (*S. mutans*) is the major etiological agent for dental caries. Nicotine is the addictive ingredient present in tobacco and has been shown to affect the growth and metabolism of oral bacteria, specifically *S. mutans*. Cigarette smoke condensate (CSC) contains all the chemicals present in cigarette smoke. Dissolvable tobacco products are new tobacco products that do not require one to light up, but may still harm oral tissues. This project examines the effects of *S. mutans* exposed to these chemicals on human endothelial cells in terms of cytotoxicity and cytokine/growth factor expression. *S. mutans* treated with these tobacco components are hypothesized to increase the expression of pro-inflammatory cytokines/growth factors from endothelial as compared to the controls. *S. mutans* was grown with each of the reagents for eight hours and then the bacterial cells and supernatants separated. Protein assays were used to determine the protein amounts of the cells and in the supernatant. The cytotoxicity of each will be determined by lactate dehydrogenase (LDH) assays. Non-toxic amounts of the bacterial cells and supernatants will then be used to treat endothelial cells for three days before the conditioned media collected and analyzed by cytokine/growth factor protein arrays. The protein assays showed that the protein levels were lower in tobacco treated cells, while the supernatants showed similar protein concentrations throughout. It is hypothesized that the treated bacteria cell will increase cytokines/growth factors that increase inflammation and lead to vascular issues.

P81 The In vitro Responses of Neutrophils to Different Tobacco Smoke Components.

N.K. AL-SHIBANI*, M.J. KOWOLIK, L.J. WINDSOR (Indiana University School of Dentistry)

Introduction: Periodontal disease is an inflammatory process that results in the destruction of the supporting tissues of the teeth. Matrix metalloproteinases (MMPs) are a family of proteinases whose primary purpose may be the degradation of the extracellular matrix. Neutrophils are believed to be the primary mediators of host responses to periodontal pathogens and are involved in the production of reactive oxygen species (ROS), which are primarily released to kill the bacteria. However, the extracellular release of ROS also results in collateral damage to the surrounding tissues. Tobacco smokers have an increased risk, incidence and severity of periodontal disease as evidenced by increased gingival

recession, tooth loss, and periodontal destruction. Objective: To investigate the effects of four different chemicals found in tobacco smoke (2-naphthylaminethylamine, hydroquinone, acrolein and acetyldehyde) with and without *Porphyromonas gingivalis* (*P. gingivalis*) on the production of ROS from neutrophils and their release of MMP-9. Methods: Chemiluminescence (CL) assays were performed to quantitate ROS released from the neutrophils and the conditioned media was analyzed by Western blots to determine the release of MMP-9. Results: *P. gingivalis* increased the release of the ROS. However when combined with 2-naphthylamine, hydroquinone and acrolein, ROS production decreased significantly masking the effects of *P. gingivalis* (all p-values < 0.05). Western blots showed decreased MMP-9 release from the cells after treatment with hydroquinone and acrolein that was statistically significant (all p-values < 0.05). Conclusion: Tobacco smoke components used in this study has the potential of decreasing ROS activity of neutrophils treated with *P. gingivalis* and also decreasing MMP-9 release.

P82 Impact of Promotions on Awareness, Trial, and Interest in Dissolvable Tobacco.

L.M. ROMITO*¹, M.K.SAXTON² (Indiana University School of Dentistry; ²Kelley School of Business, Indiana University-Purdue University Indianapolis)

The purpose of the study was to determine public awareness and trial of Camel Dissolvables (Orbs, Sticks & Strips) and the effectiveness of their promotions in the Indiana test market. An internet-based market research firm was used to obtain a stratified sample of central Indiana adult smokers and nonsmokers (N=472). Male smokers were oversampled. A 63-item survey instrument piloted in 2009 was used for data collection. Of the total respondents, 31.2% were aware of Camel Dissolvables, 4.5% had tried them and 9.7% were likely to try Camel Dissolvables. Tobacco use was a significant predictor of all three outcomes; dual users were more likely to be familiar with, try and be interested in trying the Dissolvables than mono-tobacco users and non-users (p<0.01). Male gender was only a significant predictor for likelihood of trial (p<0.01). Education was only a significant predictor of trial (p<0.05). Familiarity was predicted by in-store ads, magazine ads and mail promotions. Trial was predicted by having seen magazine ads. Likelihood of trial was predicted by website exposure. Of those who reported trying Camel Dissolvables (N=37), 49% no longer use them, 43% use them some days, and 8% use them daily. No non-smokers who tried the Dissolvables reported continued use; 87% of dual users continued use, and 26% of mono-tobacco users continued using them (p<.01). Overall, consumer awareness, interest and trial were low. However, exposure to product promotions was effective at increasing awareness, trial and likelihood of trial. Smokers and particularly, male dual tobacco users appear most affected by Camel Dissolvable tobacco promotions. Supported by the IU Kelley School of Business and the IUSD Tobacco Cessation & Biobehavioral Group.

P83 388 Commercial Antique Postcards (1900-1934): Evolution of Women's Smoking Behavior.

A. CHRISTEN^{1, 2*}, J. CHRISTEN (Indiana University School of Dentistry; Fairbanks Hospital, Indianapolis)

During the first 35 years of the 20th century, millions of U.S. and European novelty postcards covering a wide variety of topics were shipped annually to world-wide markets. Under today's scrutiny, these cards provide a valuable source of information regarding societal issues, behavioral patterns and trends in tobacco use. The authors have accumulated and studied 388 distinct, antique, commercial postcards which portray adult women smoking. Dated between 1900 and 1934, none of them had been issued by tobacco companies. Findings: Of this sample, 149 (38%) are actual photographs and 239 (62%) are drawings. These cards, from 21 countries, are listed here by production percentage: United States (32%); France (22%); Germany (19%); England (14%). Belgium and Italy (both 4%); and Sweden (2%). Algiers, Austria, Czechoslovakia, Egypt, Holland, Hungary, Martinique, Mexico, Norway, Philippines, Russia, Spain, Switzerland and Tunisia individually produced less than 1 percent. In spite of the strong moral

opposition to women's cigarette use during that period, these novel postcards were not basically designed to be either judgmental or promotional. In our collection, 93 cards (24%) illustrate men experiencing romantic reveries of attractive women, bellowing from their exhaled smoke. Forty postcards (10%) depict men and women intimately smoking together, while twenty four (6%) show women who are engaged in tobacco-induced flights of fancy. Only eighteen cards (5%) showed women smoking with other women. Results indicate that these cards, emphasized three themes: romance, fantasy, and women's emancipation. By 1918, these beautiful, daring females were becoming significant role models for gender equality, a goal which included the right to smoke openly.

P84 Tobacco Cessation: Comparing Smokers With and Without Substance Abuse History.

S. BENNETT^{1*}, P. KELLY¹, A. CHRISTEN^{1,2}, L.M. ROMITO¹ (¹Indiana University School of Dentistry; Fairbanks Hospital)

Smoking cessation has been suggested to be more difficult for individuals with a history of chemical dependence. Previous research suggests that such individuals experience a higher intensity of addiction to tobacco, and during smoking cessation they may be more likely to demonstrate an increase in negative affect and unfavorable scores on psychometric assessments compared to smokers without a substance abuse history. From 1992-2004, The Indiana University Nicotine Dependence Program (IUNDP) treated over 1200 patients using an approach based on the Mayo Clinic protocol which assesses the behavioral, social, and physiological aspects of tobacco and nicotine dependence. Subsequently, the IUNDP was instituted at Fairbanks Hospital's addictions treatment center to address tobacco use among the patients and staff. Charts of individuals who completed nicotine dependence treatment (1992-2011) were selected from IU School of Dentistry and Fairbanks Hospital for retrospective analysis. Inclusion criteria for chart selection consisted of the availability of complete pre-and post quit measures for a minimum of four total appointments, and two post-quit appointments. Reviewed were 107 charts from patients without a history of chemical dependence (ND) and 123 from those with a history of chemical dependence (CD). Student researchers, trained to a standardized protocol, captured 16 tobacco use and demographic variables, and 12 post-quit treatment measures. Comparisons between the CD and ND groups were made using Pearson chi-square tests for binary data, Wilcoxon rank sum tests for all other data, and Wilcoxon signed rank tests for changes between time periods. Compared to the ND group, smokers in the CD group were more likely to be male, and displayed a statistically significant ($p < 0.05$) increase in the following: sensorimotor handling scores of the Horn psychological test of nicotine dependence, negative mood, anxiety, restlessness, and average withdrawal scores. Additionally, over the course of treatment, compared to ND smokers, CD smokers had significantly less decrease in anger, but a greater decrease in frustration ($p < 0.05$). Despite some differences, smokers with and without a history of substance abuse closely paralleled each other in their tobacco-related addiction parameters. Results strongly suggest that smokers with a history of chemical dependence have greater difficulty during smoking cessation therapy, particularly with respect to addiction-related sensorimotor manipulation and psychological withdrawal symptoms.

P85 A Comprehensive Program for Tobacco Dependence Education at IUSD.

R. MANDIWALA^{1*}, L.M. ROMITO² (¹Indiana University School of Medicine; ²Indiana University School of Dentistry)

Tobacco use is the leading preventable cause of death in the US and a significant risk factor for oral diseases. Therefore, it is essential that dentists address tobacco dependence in their patient populations. Hence, a goal is to provide pre-doctoral students an environment which will enhance their motivation, confidence and skills in delivering evidence-based tobacco dependence treatment during school and after graduation. The study objective was to evaluate the tobacco dependence education (TDE) components of

the current 4-year pre-doctoral curriculum at Indiana University School of Dentistry (IUSD) and generate specific recommendations for program development based on the outcome. Didactic and clinical courses were reviewed for the presence of TDE components and the level to which these components were vertically and horizontally integrated into the curriculum. Results indicate TDE is offered primarily during the first two years via problem-based learning cases and didactic coursework. TDE components in years 3 and 4 appear to be limited and sporadic. Moreover, the curriculum lacks a comprehensive clinical program of tobacco dependence treatment for the School's patient population. Considering IUSD's mission, environment and resources, several key recommendations were made to improve TDE in the pre-doctoral curriculum. These include: incremental changes in didactic courses to better integrate TDE both horizontally and vertically across the curriculum, the development of a systematic approach to addressing tobacco dependence in the Comprehensive Care clinics, and faculty development to support the clinical program. Currently TDE is not delivered in a comprehensive and sequential manner across the pre-doctoral curriculum. To address these issues, specific recommendations for program enhancement have been formulated.

P86 Effect of Nicotine on Growth and Metabolism of *Streptococcus mutans*. R. HUANG*, M. LI, R.L. GREGORY (Indiana University School of Dentistry)

Streptococcus mutans is a key contributor to dental caries. Smokers have increased caries, but the association between tobacco, nicotine, caries and *S. mutans* growth is little investigated. Seven *S. mutans* strains were used in the present study: UA159, UA130, 10449, A32-2, NG8, LM7, and OMZ175. The minimum inhibitory concentration (MIC), minimum bactericidal concentration (MBC), minimum biofilm inhibitory concentration (MBIC), planktonic cell growth, biofilm formation, and biofilm metabolism of the seven strains treated with different concentrations of nicotine (0-32 mg/ml) were investigated. The MIC, MBC and MBIC were 16 mg/ml (0.1 M/ml), 32 mg/ml (0.2 M/ml), and 16 mg/ml (0.1 M/ml), respectively, for most of the *S. mutans* strains. Growth of planktonic *S. mutans* cells was significantly repressed by high nicotine concentrations (2.0-8.0 mg/ml), only strain A32-2 demonstrated enhancement at low nicotine concentrations (0.25-0.5 mg/ml). Biofilm formation and metabolic activity of *S. mutans* was increased in a nicotine-dependent manner up to 16.0 mg/ml. Nicotine enhances *S. mutans* biofilm formation and biofilm metabolic activity. These results suggest smoking can increase the development of caries by fostering greater *S. mutans* biofilm formation on tooth surfaces. This work was partially funded by the Indiana University- Purdue University Tobacco Cessation and Biobehavioral Signature Group, and Indiana University School of Dentistry Ph.D. Student Research Fund.

P87 EGCG Inhibits TNF α -Induced NF κ B Activation in Nicotine Treated Epithelium. J. SHANGO*, M. WHEATER (University of Detroit Mercy School of Dentistry)

Objectives: To determine if EGCG inhibits TNF α -induced phosphorylation and activation of NF κ B in nicotine-treated cultured human oral epithelial cells. Methods: Commercially available human oral epithelial cells (ScienCell, Carlsbad, CA) were treated for 24 hours with 0.1 mM nicotine, then pre-treated or not with 10 μ g/ml EGCG. Cells were additionally treated with 10 μ g/ml TNF α for 10, 20, or 30 minutes. The cells were then processed *in situ* to determine levels of NF κ B serine468 and serine536 phosphorylation as well as total levels of NF κ B (FACE NF κ B p65 profiler in-cell phosphorylation ELISA, Active Motif, Carlsbad, CA). Data were calculated as relative percentages of total cellular NF κ B phosphorylation. Whole-cell extracts of similarly treated cells subsequently were assayed for NF κ B subunit activation (TransAM NF κ B Family ELISA). Statistical analysis was completed using ANOVA and Tukey post-test with probability set at $p < 0.05$. Results: TNF α -induced stimulation of NF κ B phosphorylation and activation was similar in nicotine- and non-nicotine-treated cells. Serine468 levels were increased in cells treated with nicotine, EGCG and TNF α compared to cells treated with nicotine

and TNF α . In contrast, at 30 minutes of TNF α stimulation, serine536 phosphorylation was reduced in cells treated with EGCG. Of the five NF κ B family members analyzed (RelA/p65, p50, c-Rel, p52, and RelB), only p65 and p50 showed effects of EGCG treatment. EGCG significantly inhibited the activation of p65 and p50 in nicotine- and TNF α -treated oral epithelial cells. Conclusions: EGCG appears to suppress the activation of the p65/p50 heterodimer of NF κ B in nicotine and TNF α -stimulated cells. Suppression of NF κ B may explain, at least in part, why EGCG can inhibit the secretion of pro-inflammatory interleukins such as IL-8. Continued examination of the cellular function of EGCG may lead to its use as a natural inhibitor of oral inflammation in patients who use nicotine.

P88 Nicotine Effects on Biofilm in *Comc* Gene-Deficient *Streptococcus mutans*. B. SCHEER*, R.L. GREGORY (Indiana University School of Dentistry)

Objective: Quorum sensing is the ability of bacteria to detect the presence of and density of other bacteria of the same and different species in the local environment. This concept is important to biofilm studies, because it regulates the formation and maturation of biofilm, as well as symbiotic and competitive relationships among biofilm species. This study investigated the role that nicotine has on one of the quorum sensing mechanisms in *Streptococcus mutans* (*S. mutans*), the *com* system. Methods: *S. mutans* UA159 and *S. mutans comC* gene-deficient strains were compared by measuring sucrose-dependent adherence (SDA) and sucrose-independent adherence (SIDA) of each strain. *comC* produces competence-stimulating peptide (CSP) in the *com* pathway, without which the entire system is non-functional. By detecting differences in SDA or SIDA between these otherwise identical strains of bacteria, it can be determined whether or not nicotine affects the *com* system with respect to biofilm formation. Results: Data suggest that there is significantly more ($p < 0.05$) SDA and SIDA in UA159 than in the *comC* gene-deficient strain at 0, 0.25, 1, and 8mg/ml of nicotine. There is significantly less SIDA in the *comC* gene-deficient strain at nicotine concentrations of 0.25 and 1mg/ml than when nicotine was not present, but no significant difference in SDA. There is significantly more SIDA in the UA159 strain at nicotine concentrations of 1 and 8mg/ml than when nicotine was not present, but no significant difference in SIDA. Conclusion: These data suggest that without the *com* system, biofilm formation is inhibited by nicotine through both the SDA and SIDA mechanisms. In addition, the presence of nicotine causes an increase in SIDA in UA159, and a decrease in SDA in the *comC* gene-deficient mutant. Given these data, it is likely that nicotine stimulates biofilm formation at least in part through the SIDA mechanism via the *com* pathway.

P89 Caries Prevalence in Tobacco Using Patients in a Dental School. B. SHAMO*, S. CHITRE, J.M. LOEWEN, M. SAVAYA (University of Detroit Mercy School of Dentistry)

Objective: The aim of this study was to determine whether tobacco use is a risk factor for caries. Tobacco use (TU) imposes an enormous burden for public health. More than 4 million deaths are related to TU every year. Tobacco that is smoked is used primarily in the forms of cigarettes, pipes, and cigars. Smokeless tobacco is used as snuff and chewing tobacco. Studies have shown that over 1 billion adults presently use tobacco. TU is one of the top causes of oral diseases such as oral cancer and periodontal disease. Other implications for oral health include discoloration of teeth and increased calculus buildup. Methods: Investigators conducted a survey of patients' electronic health records from the participating institution. Data was confidential and was reported in aggregate from randomly chosen participants ($n=100$). Survey question content included patient oral hygiene habits and details regarding tobacco use, such as how much and how long tobacco has been used. Results: Evaluation of survey results found that 38% of the patients were current tobacco users and 46% have never used tobacco. The main form of tobacco used by current smokers was cigarettes. 10% of cigarette smokers also smoked cigars. 46% of the current smokers use tobacco 16-20 times daily and about 40% use it less than ten times. 60% of

participants were high-risk for caries. 29% have less than 5 carious lesions, 30% have 5-10, 23% have 10-15 and 18% have more than 15 carious lesions. 55% of the participants indicated brushing frequency of 2-3 times per day. Conclusions: Our investigation concluded that 1) there is a strong association between increased caries and TU and 2) a negative correlation exists between TU and oral hygiene. Emphasis on tobacco cessation should be an important step in oral hygiene instruction.

Clinical Case Reports

AESTHETIC DENTISTRY

CC1 Clinical Treatment of Extrinsic and Intrinsic Staining. L. ALLISON*, S. CHO (Indiana University School of Dentistry)

Extrinsic and intrinsic staining presents a challenge for patients and dentists desiring comprehensive and esthetic dental treatment. Extrinsic stains arise from the surface accumulation of exogenous pigment. These stains are most commonly caused by bacteria. Other sources include extensive use of tobacco, tea, coffee or other dietary sources. Many medications can also cause discoloration such as stannous fluoride and chlorhexidine. Extrinsic stains are managed with a multitude of approaches ranging from whitening procedures, microabrasives, oral hygiene behaviors, and diets. Intrinsic staining are discolorations produced by the deposition of systemically circulating substances during tooth development. Many diseases and medications are demonstrated in the dentition with characteristic discolorations. The most common intrinsic discoloration caused by a medication is from tetracycline, a wide spectrum antibiotic that produces discoloration in teeth if taken between 4 months in utero to 7 years old. Tetracycline staining varies from bright yellow to blue black. Tetracycline stain deposits predominantly in dentin and cementum therefore more intensive treatment modalities are required. The purpose of this report is to present an example of comprehensive and esthetic dental treatment of a patient with moderate to severe tetracycline staining and 30 pack/year smoking history. We recommended smoking cessation to improve the patient's oral and overall health. Patient received scaling and root planing, oral health education, and motivation for diet modification, smoking cessation, and porcelain fused to metal crowns on the six maxillary anterior teeth. The comprehensive approach to the patient's intrinsic tetracycline staining and extrinsic tobacco staining was successful in attaining the patient's ultimate esthetic dental treatment desires.

DENTAL HYGIENE

CC2 Importance of Proper Treatment Planning and Co-Diagnosis. A. HODGE, A. SHOBE*, L.L. COAN (Indiana University School of Dentistry)

Objective: The objective of this clinical case presentation is to educate dental healthcare providers on the potential for mistreatment and supervised neglect which may result from improper treatment planning in a periodontally involved patient. Also, the objective is to demonstrate the importance of co-diagnosis between the patient and healthcare provider in obtaining informed consent. Background: A 51 year old male presented in 2003 for initial periodontal therapy. Over the next several years of treatment the regular recall intervals were not maintained by the patient. During the course of the past eight and a half years of intermittent treatment, the patient's periodontal condition worsened, evidenced by an increase in clinical attachment level. Clinical examination: The patient presented to the dental hygiene clinic in

February 2012. The clinical examination revealed generalized moderate and localized severe chronic periodontitis evidenced by clinical attachment level of 3-14mm. Additionally, there were clinical and radiographic evidence of furcation involvements, mobility and abscesses.

Treatment: The suggested dental hygiene treatment plan was scaling and root planning of the entire dentition, followed by a tissue re-evaluation to evaluate success of treatment and establish an appropriate recare interval. Additionally, consultation will be provided to evaluate the need for referral to the Graduate Periodontal clinic for examination and follow up. To enable the patient to accurately co-diagnose and obtain an informed consent the disease process was described using radiographs and educational material. Open-ended questions and transference of ownership were also utilized to obtain an informed consent. Results: Upon completion of the periodontal therapy we anticipate seeing evidence of maintained clinical attachment levels or 1-2mm of reattachment, minimal bleeding on probing and healthier tissues. Also, we expect the patient to have a clearer understanding of the disease process and his role in maintaining the state of his periodontium. Further, the patient will be referred to the graduate periodontal clinic after nonsurgical periodontal therapy is complete to determine the pulpal status of specified teeth and be evaluated for regenerative periodontal therapy.

CC3 Effectiveness of Periodontal Treatment to the Medically Compromised. D. CROOK, A. LANDSTOFFER*, L.L. COAN (Indiana University School of Dentistry)

Objective: The objective of this case report is to provide a summary of treatment provided to a patient with multiple medical conditions which impacted the effectiveness of providing comprehensive dental hygiene care. Background: An 80 year old female presented to the clinic with a chief complaint of “my teeth do not feel clean”. She had been seen for routine 6 month prophylaxis at a private practice for 15 years prior to reporting to IUSD. The patient reports no history of having had scaling and root planing. The patient has a positive medical history having several systemic conditions including COPD, hypertension, osteoarthritis, and osteoporosis all of which are controlled with medications. The patient has a history of inability to be placed in the supine position during dental-related treatment. Clinical examination: The patient revealed signs of chronic periodontitis (CAL 3-6mm), moderate-to-heavy calculus formation, crowded dentition and complained of symptoms of xerostomia. Treatment: A full mouth series of radiographs were taken, oral hygiene instructions provided which included suggestions for controlling xerostomia, and four quadrants of scaling and root planning were provided. Three weeks following initial therapy, reassessment of the periodontium was completed. Patient was then placed on a three month recare cycle. Results: At the three month reassessment, no significant changes were found in the CAL from the initial readings. Additionally slight bleeding was present throughout the dentition indicating less than favorable results. It was determined that the non-surgical periodontal therapy resulted in minor benefit if any. At subsequent appointments the patient will be assessed for periodontal referral to the IUSD Graduate Periodontics clinic. Conclusions: Patients with multiple medical conditions require a comprehensive approach to determining appropriate dental hygiene services. Collaboration with all dental professionals available will assure that patients with special needs receive the best care possible.

CC4 Modification of Treatment for a Special Needs Patient. A.K. HEATH*, K. STUTLER, L.L. COAN (Indiana University School of Dentistry)

Objective: The objective of this clinical case presentation is to report treatment administered for a special needs patient which resulted in the need for modification in ways an allied health professional approached providing services. Background: A 21 year old special needs patient diagnosed as an infant with Cerebral Palsy could not be transferred to the dental chair for treatment due to lack of balance. The chief complaint identified by the patient was that he “needed his teeth cleaned” as he had not had any dental hygiene services in several years. The nurse’s aide providing the patient’s daily oral hygiene care stated that “it was difficult to floss his teeth.” The patient reported to the Indiana University School of Dentistry dental hygiene clinic for professional dental care. Clinical examination: Moderate-severe plaque-induced gingivitis was present throughout the entire mouth evidenced by dark pink, rolled, and soft tissue and a high plaque index. Several 4mm pseudo-pockets were present around the molars. The patient also presented with moderate-heavy, supra and sub-gingival calculus throughout. Treatment: A prophylaxis was completed on the patient, along with an introduction to many useful oral hygiene aids and fluoride treatments. The nurse’s aide was educated on the correct use of oral hygiene aids and fluoride toothpaste. All dental hygiene treatment was provided to the patient from the wheel chair. Due to the patient’s frequent fatigue, every appointment was shortened to an hour and a half. Results: Before treatment there were over ten teeth with bleeding points and after treatment only two bleeding points were present. The patient’s initial plaque score was 46%. At the final visit, the patient had only localized mild gingivitis, demonstrating a decrease in plaque accumulation. The plaque score had been reduced to 15%. The patient was placed on a 6 month recall cycle. Conclusions: Success from the provided dental hygiene services was made possible by collaboration between the dental hygiene healthcare provider, the patient and the nurse’s aide. This effort resulted in improvement in homecare and general oral health status.

CC5 Collaboration in the Management of a Non-surgical Periodontal Therapy Patient. J. CAIRD, F. DEWEESE*, M.L. MEADOWS (Indiana University School of Dentistry)

Objective: The objective of this presentation is to present a clinical case in which it was difficult to obtain anesthesia that would allow non-surgical periodontal therapy to be completed in a timely manner. Background: A 44 year old female patient presents with a desire to have her, “gums look normal and to remove black stuff from her teeth.” The patient’s medical history was positive for diabetes Type II, smoking, asthma, hypertension, and osteoarthritis. She reported her last dental visit was 3 years ago. This case was selected because of the severity of her periodontal condition and the unique circumstances that led to a periodontal referral before initial scaling and root planing were completed. Clinical examination: Patient presented with severe plaque/calculus induced gingivitis as evidenced by dark red, blunted, swollen gingival tissues and moderate bleeding on probing. Patient also presented with chronic periodontitis as evidenced by 4-9mm CAL and generalized radiographic evidence of severe bone loss. Treatment: Patient was treatment planned for 4 quadrants of scaling and root planing (SRP) using local anesthesia for management of pain, with evaluation for possible referral to a periodontist for further treatment after tissue re-evaluation after SRP. Treatment began on the lower left quadrant, but patient had significant difficulty with sensitivity during scaling even after local anesthesia. As a result, multiple (4) appointments were required to perform SRP in a single quadrant. Due to the complex medical history, extensive periodontitis and difficulty being anesthetized, a consultation

was obtained with Graduate Periodontics. Options presented by the resident included IV sedation for pain management during the completion of the SRP. The patient was transferred to a resident for continuation of non-surgical periodontal therapy. Complete local anesthesia was achieved by local injections using Lidocaine 2% with epinephrine and Polocaine 3%. SRP was completed using Piezoelectric Scaler in two appointments. Results: This patient was a relative of the DH student, had multiple medical issues, deep pocketing with tenacious calculus and significant anxiety. In the DH process of care, the best interest of the patient is a priority in the decision making process of referrals. To optimize care, this patient was referred to a Graduate Periodontal resident with advanced experience in treating 6-9mm pockets and in patient anxiety management. The hygiene student will be completing a tissue re-evaluation to assess the outcomes of non-surgical periodontal therapy.

CC6 Non-Surgical Periodontal Therapy in a Patient With Tobacco Use and Poor Oral Hygiene. L. ABBOTT*, A. GERINGER, M.L. MEADOWS (Indiana University School of Dentistry)

Objective: The objective of this clinical case presentation is to evaluate the outcomes of nonsurgical periodontal therapy by a dental hygiene student for a periodontally involved patient with tobacco use and poor oral hygiene risk factors. Background: A 75 year old patient presented with a chief complaint of periodontal maintenance. Upon further assessment of the patient's condition, it was determined that his periodontal status appeared to have worsened since his previous appointment. After questioning, it was revealed that he was a long term tobacco user. The intraoral examination revealed poor oral hygiene. Clinical examination: 29 sites showed evidence of increased probing depths since his previous charting. Calculus and plaque were generalized and extensive. Generalized moderate plaque induced marginal and papillary gingivitis were present. Bleeding index was 50%. Plaque index was 59%. Generalized moderate chronic periodontitis was present. An exudate of undetermined origin was observed in the alveolar mucosa between #23 and #24. All other intraoral and extraoral findings were within normal limits. Treatment: Patient was treated with four quadrants of scaling and root planing, followed by a four week tissue re-evaluation. Patient also received tobacco cessation counseling and thorough oral hygiene instructions. Results: At the tissue re-evaluation, the patient presented with improved gingival health as evidenced by changes in color, contour consistency, and a bleeding index of 6%. Probing depths improved in 63 sites by 1-2mm. His plaque index was 32%. Based on the findings at the re-evaluation, it was concluded that while certain areas improved with scaling and root planing therapy, other areas did not respond as well. This patient should continue being seen at 3 month intervals for periodontal maintenance. There was no resolution of the exudate. The patient was referred to the Graduate Periodontal Department for evaluation of this area.

CC7 Are Hypertension and Plaque Biofilm Associated With the Success of Non-Surgical Periodontal Therapy? M. FLOOK*, K. GOODMAN, M.L. MEADOWS (Indiana University School of Dentistry)

Objective: The objective of this clinical case presentation is to evaluate the outcomes of non-surgical periodontal therapy on a patient with uncontrolled hypertension and poor oral hygiene. Background: A 60 year old patient presents with a chief complaint of "wanting my teeth cleaned." Medical history was positive for hypertension. He reported a previous "deep cleaning"

approximately 10 years ago. Patient seemed to feel destined to lose his teeth and reported that his “siblings had lost their teeth at a young age.” Clinical examination: At the initial assessment, this patient presented with clinical attachment levels ranging from 2-7 mm, uncontrolled hypertension (BP 142/102 mmHg RAS), and poor plaque control (40%). Based on the assessment, scaling and root planing (SRP) in all four quadrants was concluded to be the best treatment option for this patient. Treatment: The patient was referred to his physician for evaluation of his blood pressure prior to beginning SRP. Patient was prescribed Prinzide by his physician and at the subsequent appointment his BP was 125/76 mmHg RAS. Scaling and root planing were performed in all four quadrants, followed by a tissue re-evaluation four weeks post treatment. Results: It is important to note that as a part of the dental hygiene process of care the patient’s uncontrolled hypertension was addressed: the patient was made aware of his condition and a referral to his physician was made. Since the patient complied with referral and subsequently began medication that reduced his blood pressure to a safe level for dental care, the proposed non-surgical periodontal therapy was able to be completed. Overall, improvement in probing depths and plaque score were noted; however, there are a few areas that did not respond to SRP provided. A periodontal referral was not given at this time but may need to be reconsidered at the next 3 month recall based on findings at that time.

CC8 Non-Surgical Therapy on an Advanced Periodontitis Patient. M. DAVENPORT*, M. LYNN, M.L. MEADOWS (Indiana University School of Dentistry)

Objective: The objective of this clinical case presentation is to evaluate the outcomes of non-surgical periodontal therapy by a dental hygiene student and a periodontal resident on a patient with advanced periodontitis. Background: A 46 year old Caucasian female patient presented with a chief complaint of “I need to get my teeth cleaned and checked.” The patient reported no dental care for over 7 years. Her medical history was essentially negative. The patient stated that she brushed once a day and rarely flossed. Clinical examination: Revealed advanced periodontal disease with probing depths ranging from 1-10 mm with clinical attachment levels ranging from 1-11 mm. Patient also presented with generalized moderate plaque induced gingivitis. The intraoral radiographs revealed the patient had generalized severe bone loss with many vertical defects. Treatment by DH Student: Prescription of Peridex was given. 4 quadrants of scaling and root planing (SRP), with extensive oral hygiene instructions (OHI), and tissue re-evaluation were completed. Tissue re-evaluation revealed 1 mm improvement in probing depths in some areas but some localized advancement of probing depths. Patient was referred to Graduate Periodontics Department. Results by DH Student: The SRP resulted in some improvement in bleeding and minimal changes in probing depths. Patient’s improved OH may have resulted in the improved gingival health. Treatment by Periodontal Resident: Blood tests were ordered to rule out any systemic conditions. 4 quadrants of SRP, OHI and tissue re-evaluation were performed by resident, possibly followed by 4 quadrants of open flap debridement and select extractions. Results by Periodontal Resident: Blood test results were negative for any systemic conditions. The SRP resulted in improvement in gingival health and generalized 1-3 mm improvement of probing depths with some advancement of recession. Gingival health continued to demonstrate improvement as measured by reduced bleeding, improved color and contour.

CC9 Non-Surgical Periodontal Therapy and Patient Education for a Patient with Generalized Severe Gingivitis. H.A. LAMBERT*, J. BROWNING, N.A. YOUNG (Indiana University School of Dentistry)

Objective: This clinical case presentation reports the Dental Hygiene Process of Care in the provision of nonsurgical periodontal therapy for a patient exhibiting moderate-to-severe periodontal disease. Background: A 35 year-old male presented to the IUSD Dental Hygiene Clinic for periodontal maintenance. He had received partial periodontal treatment 3 months prior as a dental board patient. Clinical Examination: Medical history was negative except for social drinking and smoking occasionally on weekends. He reported a family history of diabetes. He exhibited severe, chronic periodontitis, generalized bleeding, and significant calculus deposits. The patient reported daily brushing and flossing. High caries risk status was identified. Treatment: Patient was treated with two quadrants of scaling and root planing, oral hygiene instructions, and followed up by a tissue evaluation. Results: The one (1) month perio re-evaluation results revealed slight reduction in probing depths, and decreased bleeding, but there was calculus re-accumulation on the mandibular teeth. Periodontal findings revealed improved probing depths and bleeding, but changes were not clinically significant overall. At the 3-month recall appointment, however, gingival status, probing depths, and bleeding had regressed, generalized moderate to heavy calculus deposits had reformed. Possible reasons for lack of improved oral health status will be discussed. In consultation with the supervising dentist it was determined that a referral to a periodontist would occur at the next periodontal maintenance appointment if the conditions had not improved.

CC10 Non-Surgical Periodontal Therapy in a Patient with Systemic Disease. H. WETZEL*, S. TURNER, N.A. YOUNG (Indiana University School of Dentistry)

Objective: A case presentation will be discussed to demonstrate the impact of non-surgical periodontal therapy on an individual exhibiting poor oral hygiene, history of systemic disease and tobacco use. Decision-making related to the need for periodontal referral will also be discussed. Background: A 48-year-old male presented to the IUSD Dental Hygiene Clinic with a chief complaint of “cleaning” and exam. Patient stated that he received scaling and root planing treatment four years prior to seeking treatment at IUSD. Medical history revealed HIV+ status and tobacco use. Clinical examination: Assessment revealed moderate submarginal calculus, generalized moderate staining, and overall poor oral hygiene. He presented with generalized, chronic periodontitis and gingivitis. Extra-oral examination revealed swollen lymph nodes in neck. Patient reported brushing twice daily, flossing once daily and using Crest Pro-Health® mouthrinse occasionally. Initial Plaque Index was 34%. Treatment: Patient received scaling and root planing in four quadrants. Four weeks after scaling and root planing were completed patient was seen for a tissue re-evaluation. Oral hygiene practices were reviewed and instructions provided at each visit. Results: There were no clinically significant changes seen at the periodontal re-evaluation appointment four weeks post-treatment. Only slight improvements in clinical attachment levels and bleeding points were observed. Patient reportedly complied with home care instructions, but deposit and stain re-accumulation did not support his assessment of good compliance. Possible reasons for lack of improvement were considered in terms of need for further treatment. Due to poor response of gingival tissue, clinical attachment level, bleeding upon probing, history of tobacco use and HIV+ status, the patient was referred to graduate periodontics for further evaluation and treatment.

CC11 Transitioning Patient's Concern for Esthetics Towards Needed Periodontal Therapy.
E. RAYLS*, M. WHITE, N.A. YOUNG (Indiana University School of Dentistry)

Objective: The objective of this case study was to transition the patient's desire for an esthetically pleasing dentition towards an understanding of how her periodontal health would impact her overall esthetic outcome. Background: A 57 year-old African-American female presented to IUSD screening clinic in 2008 but chose not to return after presentation of a treatment plan due to the length of time the treatment would require. She returned to the DH clinic in 2011 seeking to resume treatment because she had recently acquired a position as a receptionist where she felt obligated to smile at her clients and felt embarrassed at the condition of her mouth. Her chief complaint was "I work as a receptionist at the front desk of my work place and I am embarrassed at the way my teeth look. I want to have nice teeth so I can smile at the customers." Clinical examination: Revealed generalized, chronic periodontitis evidenced by 4-8 mm CAL and localized aggressive periodontitis evidenced by 11-13mm CAL on #'s 2 and 18. Generalized, severe gingivitis evidenced by red, spongy, rolled gingiva and a bleeding score of 47% were observed. All other findings were within normal limits. Treatment: Patient underwent four (4) quadrants of scaling/root planing. Patient was taught proper sulcular brushing technique and appropriate flossing technique; supplemental home irrigation was recommended. Results: Patient tolerated treatment well and was pleased with the overall treatment procedure. A periodontal re-evaluation will take place 5 weeks post-therapy and improvements in overall periodontal conditions are anticipated. Pre and post-treatment photos will assist in demonstrating to the patient how improvements in her periodontal health have also contributed to her esthetic concerns.

CC12 The Effects of Non-Surgical Periodontal Therapy on a Patient with Chronic Periodontitis.
R. BECK*, A. LOOMIS, N. STUMP (Indiana University School of Dentistry)

Objective: The objective of this clinical case presentation is to demonstrate improved periodontal condition using the commonly accepted indicators of periodontal health following nonsurgical periodontal therapy. Background: A 33 year old patient presented with a chief complaint of "I need a deep cleaning." This patient has not seen a dentist for 15 years and after being diagnosed with HIV wanted to make a positive change to improve his oral health. Clinical examination: Revealed generalized chronic periodontitis and moderate plaque induced gingivitis. Radiographic assessment presented with generalized mild bone loss and calculus deposits. All other intraoral and extraoral findings were within normal limits. Treatment: This patient received 4 quads of scaling and root planing after receiving a full mouth gross debridement by a dental student. Results: Anticipated results post tissue re-evaluation will include use of indicators such as clinical attachment levels, bleeding, and improved gingival conditions such as pink, firm tissue.

CC13 Oral Management of a Lichen Planus Patient. M. SMITH*, K. RHEINHARDT,
P. RETTIG (Indiana University School of Dentistry)

Objective: The objective of this case presentation is to help dental professionals educate their patients with lichen planus on oral hygiene needs to maintain the integrity of the oral mucosa. Background: An African American female with a three year history of lichen planus presented to IUSD clinic for her three month periodontal maintenance. Patient was diagnosed by Dr. Zunt , Oral Pathologist, care recommended to include daily chlorhexidine rinse and avoidance of

sodium laurel sulfate containing toothpastes. Additionally, patient reported severe discomfort which had prevented her from performing any type of oral hygiene in ten days. Unsuccessful management of the disorder was due to noncompliance of recommendations, reported by patient because of the stain. Clinical examination: Intra oral exam showed bright red, spongy, extremely sensitive tissues with white striations and spontaneous bleeding, coated tongue, heavy accumulations of generalized plaque, and a large ulcerated lesion on the buccal mucosa. Manipulation of her labial mucosa caused this patient severe discomfort. Treatment: The chief complaint was to reduce the pain she was experiencing. In order to do this, an initial debridement of all biofilm was performed. Oral hygiene needs were assessed and prioritized to educate the patient on maintaining her oral health. Such topics addressed were the necessity of chlorhexidine, and proper brushing instruction that would aid in decreasing the stain it leaves behind. This is the best treatment available that effectively lowers the bacterial load and does not burn or irritate the tissues. The patient was instructed against the use of sodium laurel sulfate containing toothpastes and given *specific* products not containing this agent. Results: Post-operative visit revealed active lesions but no patient discomfort. Patient stated she was using recommended products and following an oral hygiene regimen. Conclusions: As a result of compliance with the home regimen pain was resolved.

**CC14 Early Interventions Aid In Successful Dental Outcomes. J.IANNOTTI*,
M.SORIANO, P. RETTIG (Indiana University School of Dentistry)**

Objective: The objective of this clinical case presentation is to educate health care providers to manage patients with autism and provide care for them and their dental needs. Background information: A twenty-four year old autistic female patient presented for a prophylaxis. Patient had a history of anti-seizure and antidepressant medications. Autistic patients require special communication methods. This case will be based on the patient's reactions to dental anxieties and the change in daily routine. Clinical examination: Oral examination revealed no obvious traumas common to those with autism. Anterior teeth presented with spacing throughout with signs of a swallowing tongue thrust. Plaque score was minimal. Treatment: Routine prophylaxis and exam were performed. Oral hygiene education was done with patient and caregiver and fluoride varnish applied. Results: Patient tolerated treatment well. Caries risk was unexpectedly low. Plaque was retained around all 3rd molars and quadrant two indicating patient having trouble accessing these areas. Patient demonstrated oral hygiene techniques and recommendations were made with caregiver and to consider an electric toothbrush for better plaque removal. Exam revealed no needs for restorative treatment or referral. Conclusions: It was reported that the patient's autism diagnosis and treatment began at 3 years of age. Research shows autistic individuals treated from a young age adapt better in society. This positive dental experience can be attributed to the early experiences at the dentist and since then has always looked forward to her treatments. This success demonstrates that early interventions have a positive impact on the patient's oral health and socialization. Dental professionals can benefit from organizations such as, Helping Hands in Autism, which offer great tools and workshops to successfully treating autistic patients, and advocate meeting the unmet needs of these patients.

CC15 Management of a Medically Compromised Patient with Multiple Dental Needs. M. OMBREMBOWSKI*, L. DUNWIDDIE, K. NUGENT, P. RETTIG (Indiana University School of Dentistry)

Objective: The objective of this clinical case presentation is to educate dental providers on the management of a medically compromised patient with multiple dental needs. Background: A sixty-four year old patient presented with a history of high blood pressure, a stroke within the past two years that reduced his dexterity, and a fifty year history of cigarette smoking. This patient had not accessed dental treatment within the last twenty years. Clinical examination: Clinical findings included generalized chronic periodontitis evidenced by 4-8 mm clinical attachment levels. Additional findings included mobility, furcation involvement, recession, generalized active bleeding sites, subgingival and supragingival calculus, and gross decay. Radiographically this patient presented with generalized moderate bone loss evidenced by 5-6 mm measurements from the CEJ with localized areas of severe bone loss evidenced by 7+ mm measurements. Treatment: The treatment plan consisted of four quadrants of scaling and root planning therapy and dental health education. Results: Following treatment a tissue re-evaluation was performed and resulted with a generalized improvement in clinical attachment level of 1-4 mm, gingiva appeared less red and rolled, and plaque score decreased by 42%. Conclusion: The positive results of treatment can be attributed to the scaling and root planning therapy, extensive dental education, and patient compliance.

CC16 Response to Treatment Following the Absence of Dental Care. L. RATLIFF*, K. WRIGHT, P. RETTIG (Indiana University School of Dentistry)

Objectives: The objective of this clinical case presentation is to educate dental providers on the treatment results after scaling and root planing in a patient with heavy supra and subgingival deposits. Background: A 64 year old male patient presented with a chief complaint of a cleaning and restorative treatment. He reported not having dental treatment in eight years. Clinical examination: Patient presented with generalized moderate chronic periodontitis, generalized moderate gingivitis, heavy soft and hard deposits, several obvious gross carious lesions, and severe abrasion. All other intraoral and extraoral findings were within normal limits. Treatment: Patient received four quadrants of scaling and root planing. Results: The scaling and root planing is complete and the patient will return for a tissue re-evaluation in mid-March where the final results will be recorded. Conclusion: At the tissue re-evaluation we anticipate to see improvement of the overall gingival and periodontal status.

CC17 Periodontal Therapy in Overdue Patient. C. LECHER*, M. STONE, R.H. RACKLEY (Indiana University School of Dentistry)

Objective: The objective of this clinical case presentation is to educate the dental team on treatment and outcomes of non-surgical periodontal therapy on a patient presenting with local modifying contributing factors. Background: The patient presented to the clinic with the chief complaint of “bleeding gums and bad breath.” The patient had not been seen by a dentist in over ten years due to the lack of insurance coverage. Reviewing the medical history the patient admitted to smoking a pack of cigarettes a day for the past twenty years, with the intent of quitting in the near future. Clinical Examination: Intraoral examination revealed moderate plaque induced gingivitis as evidenced by red, swollen, and bleeding tissue, as well as moderate chronic

periodontitis as evidenced by CAL 4-8mm. Generalized severe sensitivity was observed throughout the entire dentition, in addition to bleeding on probing. Treatment: The patient had scaling and root planing performed in all four quadrants with the use of 1% Lidocaine with vasoconstrictor administered for the PSA, MSA, ASA, Greater Palatine, IANB and the Long buccal injections. Following the non-surgical therapy the patient returned in six weeks for a tissue re-evaluation to gauge the effectiveness of treatment provided and to observe how the patient's home care was being performed. Results: At the tissue re-evaluation the patient's needs were assessed and it was determined the therapy provided was successful and the patient adhered to the recommendations given. There was minimal bleeding, plaque, calculus and an overall decrease in probing depths. The patient was delighted with the treatment outcomes, and assured the continuation of home care would be carried out.

CC18 Comorbidity of Uncontrolled Diabetes Mellitus and Periodontal Disease. K. LOVE*,
B. THORNBURG, R.H. RACKLEY (Indiana University School of Dentistry)

Objective: The objective of this clinical case presentation is to exhibit the link between the clinical progression of periodontal disease and uncontrolled diabetes paired with infrequent dental hygiene treatment and to further demonstrate the effectiveness of non-surgical periodontal therapy with this case. Background: A 51 year old patient presented with a chief complaint of "I need my teeth cleaned. They haven't been cleaned in five years." The patient's medical history revealed uncontrolled diabetes, a well-known risk factor for periodontitis. Initial non-surgical periodontal therapy was performed five years prior to our first appointment. The patient had not received any dental hygiene care since the initial therapy. Clinical examination: The clinical examination revealed generalized chronic moderate periodontitis and moderate diffuse gingivitis. All other intraoral and extraoral findings were within normal limits. Treatment: Four quadrants of periodontal scaling and root planing were completed on this patient. Results: Upon successful completion of treatment, the patient demonstrated significant gingival healing and generalized reduction of periodontal pocket depths. Periodontal maintenance should occur in three months.

CC19 Periodontal Treatment. K. FAHRINGER*, A. THACKER, R.H. RACKLEY (Indiana University School of Dentistry)

Objective: The objective of this case study is to show how proper treatment can improve a patient's oral health. Background: A 21 year old male patient presented with a chief complaint of "I haven't had my teeth cleaned for at least 10 years and I know they are bad." We selected this patient because he presented with generalized calculus, active decay, and severe gingivitis, which are all clinically visible. Clinical Examination: Patient presented with generalized heavy calculus. A few teeth had advanced cases of decay, which are to be extracted or restored by a dental student at a future date. Patient also presented with generalized severe gingivitis as evidenced by red, rolled, bulbous gingiva and BOP of 59%. Patient presents with 1-5 mm CAL. The pocketing appears to be pseudopocketing from the patient's severe gingivitis. The patient has generalized healthy radiographic bone levels of 1-2 mm from CEJ and localized mild bone loss in the mandibular anteriors as evidenced by bone levels of 3-4mm from CEJ. All other intraoral and extraoral findings were within normal limits. Treatment: Performed scaling and root planing in two quadrants and had tissue re-evaluation 3 weeks after final appointment. Results: Patient is still being treated. Results will be submitted when treatment is completed. We expect to see a reduction in gingivitis and an improvement in probing depths.

CC20 Effects of Long-Term Tobacco Use on the Periodontium. A. BLANE*, B. NEEDLER, S. PHILLIPS (Indiana University School of Dentistry)

Objective: The objective is to present a summary of treatment provided to a patient with a history of tobacco use resulting in negative effects on the periodontium. Background: A forty-seven year old female presented to the dental hygiene clinic with a chief complaint of “I want my teeth cleaned.” The patient reported a history of depression and a tobacco quit date of November 1, 2011 (two months prior to initial treatment) after a thirty year history of tobacco use. Clinical examination: The patient presented with generalized chronic periodontitis as evidenced by generalized clinical attachment levels of 3-6mm and moderate bleeding on probing. Treatment: The patient has received oral hygiene instructions as well as two quadrants of scaling and root planing. Continuing services will include: two quadrants of scaling and root planing and a tissue re-evaluation one month following completion of initial periodontal treatment. Results: Treatment is pending; however, a thorough assessment will be completed post-therapy. It is anticipated that the patient’s gingival and periodontal health will improve as evidenced by reduction in bleeding, firmer gingival tissue, and stable probing depths. Projected results will be determined once the initial treatment and tissue re-evaluation are completed.

CC21 The Effects of Nonsurgical Periodontal Therapy After Avoiding Dental Treatment for 15 Years Combined with Consistent Tobacco Use. M. MOGG*, A. LEGGE, S. PHILLIPS (Indiana University School of Dentistry)

Objective: The objective of this clinical case presentation is to illustrate the effects of nonsurgical periodontal therapy after avoiding dental treatment for fifteen years combined with consistent tobacco use. Background: A 54 year old male patient presented to the hygiene clinic with a chief complaint of “I haven’t seen a dentist in fifteen years and I really need my teeth cleaned.” The patient conveyed dental anxiety, yet enthusiasm for taking control of his oral health. Clinical examination: Revealed gross decay, moderate to severe periodontitis with generalized heavy subgingival calculus and a mild bleeding score. All extraoral findings were within normal limits. Intraoral findings indicated less BOP and a reddened oropharynx, consistent with tobacco use. Treatment: Patient received a prescription for Prevident, oral hygiene instructions, four quadrants of scaling and root planing with local anesthesia administered, a dental exam, and a fluoride varnish treatment. Patient also received tobacco cessation counseling. Results: Patient presented to the tissue re-evaluation with overall successful results from the nonsurgical periodontal therapy. Success was determined by improved tissue health, generalized increased probing depths and CAL. Patient was referred to OMS to remove gross decay. Patient was referred to a periodontal clinic for evaluation of one area of severe periodontitis that did not respond well to therapy. Depending on periodontal referral evaluation, patient will be on a three month recall. After tobacco cessation, patient seemed very motivated to quit smoking cigarettes. Another student contacted this patient to check up on cessation as part of graduation requirements.

CC22 The Progression of Periodontal Disease. C.B. WILLINGHAM*, D. MOLINDRE, S. PHILLIPS (Indiana University School of Dentistry)

Objective: The objective of this clinical case presentation is to associate the lack of oral home care as well as professional care to the continued periodontitis in this particular patient. Background: A 82 year old patient presents for a periodontal maintenance and dental exam. This patient has previously undergone periodontal scaling and root planing in 2004 and kept up with regular periodontal maintenance appointments. However, the patient stopped routine care for about two years and returned back to the school in 2012. Clinical examination: The clinical exam revealed moderate gingivitis and chronic periodontitis. No intra or extraoral factors affects treatment. Treatment: The patient underwent an in depth periodontal maintenance appointment

and a periodic oral evaluation. Results: The results are to be determined on March 9th, when the patient returns for a tissue re-evaluation.

CC23 The Effects of Sugary Drinks on the Dentition. K. MOODY*, K. TAYLOR, S. PHILLIPS
(Indiana University School of Dentistry)

Objective: To demonstrate the negative effects of sugary, acidic drinks on the dentition. Background: A thirty-two (32) year old male patient presented with a chief complaint of, “I am having a lot of pain on my top, back teeth”. The patient reported drinking sugary, acidic beverages frequently throughout the day, a lack of proper oral hygiene and tobacco use. Caries is the demineralization process caused by a susceptible host, plaque biofilm, a sugary diet, and time. Tobacco has been shown to be a contributing risk factor for caries. As hygienists, a thorough caries management plan should be implemented from the caries risk assessment. Clinical examination: Revealed significant generalized demineralization with hard and soft deposits throughout the dentition and a plaque score of 52%. Patient presented with generalized moderate papillary and marginal, plaque-induced gingivitis as well as generalized chronic periodontitis with a clinical attachment level of 1-10mm. Patient also had both restorable and non-restorable caries and multiple white spot lesions. Patient presents as a high caries risk due to high fermentable carbohydrate intake, high plaque scores, current decay, and poor oral hygiene habits. The patient was deficient in all food categories having twelve (12) exposures to high fermentable carbohydrates noted in his diet diary. Treatment: Scaling and root planing (SRP) was performed on all posterior teeth with debridement on the rest of the dentition. Dietary counseling and oral hygiene instruction (OHI) was also provided. Though patient was not interested in quitting tobacco at the time, advice and information concerning tobacco cessation was provided. The patient was given a prescription for a high concentration fluoride gel (5,000ppm) to aid in caries prevention. Patient returned for tissue re-evaluation four-to-six (4-6) weeks following SRP. Results: Upon tissue re-evaluation, the treatment was deemed predominately successful. The patient’s clinical examination revealed improvement in gingival status with areas of improvement in probing depths. Patient stated he had been following the diet recommendations and had quit using tobacco in January. Patient was referred for restorative work as well as extractions of non-restorable teeth. The patient’s recall for periodontal maintenance was scheduled for three (3) months.

ENDODONTICS

CC24 Endodontic Treatment of Patients Following Radiation Therapy. A. REXFORD*,
K.J. SPOLNIK, M.M. VAIL (Indiana University School of Dentistry).

Radiation therapy in combination with surgery is a common oncologic treatment for head and neck cancers. It is a successful treatment; however, osteoradionecrosis (ORN) is a serious adverse effect. ORN is a progressive devitalization of irradiated bone that is irreversible. Some risks of developing ORN include and are not limited to, total dose of radiation, proximity of tumor in bone, dentition, and nutritional status. This clinical case report details two patients that had a history of radiation therapy greater than 65 Gy that were presented to the Graduate Endodontic Clinic for treatment as opposed to extraction due to the risk of ORN. The clinician must inform patients with a history of radiation to the head and neck of the risks associated with extraction. Endodontic treatment of nonrestorable teeth maybe necessary to prevent increased risk of ORN.

CC25 Regenerative Treatment of a Trauma-Induced Necrotic Immature Tooth.

J.K. JEPPSON*, K.J. SPOLNIK, M.M. VAIL (Indiana University School of Dentistry).

Regenerative endodontics is a biologically based procedure designed to replace damaged dentin and root structures, as well as cells of the pulp-dentin complex, by utilizing stem cells, growth factors, organ-tissue culture, and tissue engineering scaffold materials. This clinical case report details the treatment of a trauma-induced necrotic, immature, permanent central incisor by a regenerative approach, instead of the conventional apexification technique. After the diagnosis of necrosis with symptomatic apical periodontitis, the tooth was accessed and purulent drainage noted. The canal was disinfected with copious amounts of sodium hypochlorite utilizing the EndoVac irrigation system and an interim treatment of a triple antibiotic paste was placed. After the disinfection protocol was complete and the patient was asymptomatic, the periapical tissue was mechanically stimulated to induce intracanal bleeding allowing a blood clot to form just apical to the cemento-enamel junction. Mineral trioxide aggregate was placed on top of the blood clot followed by a dentin bonded resin. After 18 months, both clinical and radiographic evidence suggested a favorable biological response with this newly developed treatment protocol. This case report confirmed that successful regeneration of previously necrotic-infected canals is possible provided the canal environment can be effectively disinfected.

CC26 Comparison of Periapical Radiographs to CBCT Images. J. WHATLEY*,

K.J. SPOLNIK, M.M. VAIL (Indiana University School of Dentistry).

Cone-beam computed tomography (CBCT) has existed since the late 1990's. CBCT has the potential to revolutionize the specialty of endodontics with its increased accuracy and resolution, low radiation dosage, and low financial burden for the patients. This clinical case report details six cases comparing the use of digital radiography and CBCT. The CBCT provided further information that could not be detected on a periapical, digital radiograph. Subsequently, a definitive treatment plan was established. These cases include comparisons of digital radiographs to CBCT that enabled diagnosis of non-endodontic pathology, vertical root fractures, cracks, periapical pathosis, anatomy, complications, accessory and missed canals, and resorption. CBCT has many indications in endodontics and can be used as a great adjunct to radiographs when more information is needed. As a result, patients may not have to go through unnecessary treatment.

ORTHODONTICS

CC27 Periodontally Accelerated Osteogenic Orthodontics (PAOO) "A 2 year follow-up. E. CRUZ MARROQUIN*, O.H. RIGSBEE (Indiana University School of Dentistry)

Orthodontic patients may benefit from a new surgical technique, Periodontally Accelerated Osteogenic Orthodontics (PAOO). This procedure requires selective alveolar corticotomies and bone grafting a few days after the initiation of orthodontic treatment. This technique may decrease the duration of orthodontic treatment time by more than 50%, reduce root resorption, attenuate relapse, and significantly increase alveolar bone support. Rapid orthodontic tooth movement is induced via the surgically-induced regional acceleratory phenomenon (RAP) resulting in an increase in the rate of bone remodeling locally. Materials & methods: A 30 year old female with an Angle Class I malocclusion and severe lower anterior crowding was treated

with this new technique. A complete orthodontic and periodontal evaluation was performed including radiographs, periodontal charting, cone beam computed tomography (CBCT) and a diagnostic wax up. Orthodontic treatment was planned and then initiated two days prior to surgery. Surgery was performed under IV conscious sedation and included elevation of full thickness flaps on both mandibular and maxillary arches. Corticotomies were performed in selected sites followed by composite bone grafting in the sites and extraction of lower left lateral #23. The composite graft was composed of demineralized freeze dried allograft (DFDBA) and a xenograft material (Bio-Oss). The material was rehydrated in saline solution containing 10mg/ml of clindamycin prior grafting. Flaps were repositioned and sutured. Orthodontic adjustments were performed every two weeks. After completion of treatment, case was followed for two years presenting no significant changes in stability and no detrimental effects for the periodontium. Conclusions: Active orthodontic treatment was concluded after 10 months. Conventional orthodontics was originally estimated at twenty four months. This technique resulted in more than 50% reduction in treatment duration. This case represents the second reported use of PAOO at IUSD and promises to be an exciting adjunctive treatment option for the future, presenting good stability if patient is compliant and follows an adequate retention protocol.

PEDIATRIC DENTISTRY

CC28 Clinical Case Presentation for Enamel Hypoplasia on Pediatric Patient. M. PEZESHK*, J. CHIN (Indiana University School of Dentistry)

Purpose: This case demonstrate a pediatric patient's treatment who exhibited moderate to severe enamel hypoplasia. Background: Enamel hypoplasia is a disruption of the ameloblasts in the formation of the enamel matrix, causing a deficiency in the quantity of enamel. Hypoplasia may affect both primary and permanent teeth and can vary in shape, texture and appearance. Patterns can vary from widespread to localized areas of the dentition. Methods: An 11 year-old female patient presented with severe hypoplastic enamel on the mid-labial surface of #8 and #9, appearing as pitted enamel with areas of dark hypoplasia. Recognizing this clinical presentation as enamel hypoplasia directly affects the modality of treatment. A conservative treatment approach was taken as areas of hypomineralization provided decreased surface retention. The teeth were isolated, etched with 37% phosphoric acid, and a layer of opaque sealant was applied to mask the dark areas. Results: The conservative treatment approach used to restore the hypoplastic teeth maximized the remaining tooth structure while restoring natural form and esthetics. The patient and parent were happy with the results.

PERIODONTICS

CC29 Spontaneous Regression of Retrocuspid Papillae After Scaling and Root Planing. J. AU-YEUNG*, S. PRAKASAM. (Indiana University School of Dentistry)

Retrocuspid papillae (RCP) are circumscribed nodules that are found lingual to the mandibular cuspids on the gingival tissue. It is a poorly recognized entity that has been described in the literature as "normal" or a "variation of normal" anatomy. Levin and Cutright first described RCP in 1977 proposing that the encircling plexus of an erupting deciduous or permanent tooth causes erosion of the lingual cortical plate and the plexus anastomoses with the lingual mucosal

circulation, thereby forming the papilla. Histologically the RCP has been described as loosely-arranged delicate fibrous connective tissue with stellate and multinucleated fibroblasts. The importance of recognizing the RCP entity is to be able to differentiate it from pathologic entities it may mimic such as cysts, granulomas, tumors, congenital epulis, and abscesses. According to Berman et al, they found a 72.5% incidence of RCPs in children under 11 years of age and reported regression with aging suggesting that this is a normal anatomic structure that does not need further treatment or biopsy. Spontaneous regression of this entity has not been previously documented. The purpose of this case report is to document the rare spontaneous regression of RCP after scaling and root planing periodontal therapy with adjunctive systemic antibiotic administration. The patient was a 25 year old African American male diagnosed with generalized aggressive periodontitis that initially presented with RCP. He underwent full mouth scaling and root planing with a 5 day course of metronidazole 250mg and Amoxicillin 500mg. The clinical appearance of the RCP at initial presentation appeared robust. The patient was followed for re-evaluation and maintenance appointments over 16 months where the regression of the RCP can be observed. This case suggests that the RCP may have an inflammatory/infectious component to the lesion and periodontal therapy (SCRCP & systemic antibiotics) may lead to regression of the structure. The clinical significance of such regression is not known and needs to be explored. Additionally the premise that RCP disappears with age needs to be re-examined.

PROSTHODONTICS

CC30 Implant Placement in Previously Failed Implant Site in the Esthetic Zone. A. NISHIGORI*, J. AU-YEUNG, J. LEVON (Indiana University School of Dentistry)

It has been reported in the literature that re-implantation of dental implants in previously failed sites have higher failure rates. In the case of late implant failure there is a longer infection period which changes the quality and quantity of bone available. With bone grafting, the site should behave like a chronically infected extraction site with its first implant placement. The purpose of this case report is to demonstrate successful implant placement in a medically compromised patient with a previously failed implant site in the esthetic zone. The patient was a 27 year old Caucasian male with a history of asthma, crohn's disease, gastroesophageal reflux, hypertension, xerostomia and seizures with allergies to doxycycline and ibuprofen. The patient initially had guided bone regeneration surgery in implant site #6 using osteocel graft material followed by implant placement 4 months after with a 4x12 mm laser etched micro-channel implant. The implant failed 2 months after placement and the area was re-grafted with freeze dried bone allograft (FDBA) with titanium reinforced polytetrafluoroethylene membrane. The membrane was removed 3 months after grafting and the second 3.5x10.5 mm laser etched micro-channel implant was placed 2 months after membrane removal with cover screw placed and complete soft tissue coverage in a staged implant approach. Second stage surgery was performed at 3 months after implant placement at which point the patient was given a temporary crown on implant #6 to provide improved esthetics while contouring the soft tissue. The patient's occlusion was also evaluated and adjusted as necessary to prevent occlusal overload to the implant as well as all restorations in the arch. After temporization, the patient had a definitive implant supported cement retained porcelain fused to metal (PFM) restoration delivered to achieve health, comfort, esthetics and function. The patient's maxillary anterior teeth were also crowned to address the patient's chief complaint of wanting a whiter smile. Successful implant therapy can be performed in the esthetic zone of a medically compromised patient with a

previously failed implant site. Further studies to determine clinical parameters affecting success or failure of implant placement in chronically inflamed sites need to be investigated.

CC31 Implant Retained Overdentures for Completely Edentulous Patients with Mandibular Resection. E. ALOBAIDI*, J. LEVON (Indiana University School of Dentistry)

The prosthodontic rehabilitation of a resected mandible can be very challenging. Few of these edentulous patients with mandibular discontinuity, either being reconstructed or not; can reach their previous masticatory efficiency. Some of the factors that contribute to this decreased chewing efficiency include: compromised denture bearing area, deviation of the mandible, angular pathway closure, and compromised tongue function. The use of osseointegrated dental implants in some of these cases can lead to a distinct improvement in the retention of the final prosthesis. The increased retention can then facilitate a more effective mastication for the patient. Many times this increased masticatory function is greater than that previously obtained with a conventional prosthesis for a patient with mandibular discontinuity.

CC32 Interdisciplinary Treatment of Restorative and Removable Partial Dentures. K. CZARKOWSKI*, T. CARLSON (Indiana University School of Dentistry)

Interdisciplinary treatment is part of everyday practice. Interaction among different specialists can provide patients with more conservative and pleasing results. This clinical case report examines the comprehensive care of a 62 year old female who presented to Indiana University School of Dentistry desiring “her teeth to be fixed.” The purpose of this clinical case presentation was to restore form and function for a patient who had been lacking this for more than five years and provide comprehensive dental treatment using a multidisciplinary approach. The patient was screened, a full mouth series of radiographs completed and comprehensive treatment was planned. All necessary areas of treatment were addressed in conjunction with the patient’s ideal outcome for her oral health, which included direction restorations and removable partial dentures. The patient’s oral health status was complicated by her abundant number of medications, which was addressed before initiating treatment. Endodontics was completed on #24 and #25 with two final resin restorations, incisal resins to restore attrition on #8 and #9, a restoration was placed to restore #6 which was carious, and maxillary and mandibular partial dentures were fabricated to restore form and function. Oral hygiene education, diet modification, and patient motivation combined with appropriate comprehensive multidisciplinary dental care was provided to promote a more positive oral health future for this patient.

**Thank you to our Sponsors
for your continuing support of Research Day**

§ 20 years † 15+ years
‡ 10+ years † 5+ years

Delta Dental Foundation †
Susan E. Trobec
(517) 347-5333 ph
strobec@deltadentalmi.com

Johnson & Johnson †
Wendy Swanson
(810) 397-3482 ph
WSwanso1@its.jnj.com

Heraeus Kulzer
Aundrea Hoffman
(574) 299-5476 ph
aundrea.hoffman@heraeus.com

Procter & Gamble/Crest §
Lenny Barnette
(847) 263-0288 ph
barnette.lh@pg.com

Indiana Dental Association ‡
Jay T. Dziwlik
(317) 634-2610 ph
jay@indent.org

Shofu Dental Corporation ‡
Brian Melonakos
(760) 736-3277
brian@shofu.com

**Thank you to our Exhibitors
for your continuing support of Research Day**

§ 20 years † 15+ years
‡ 10+ years † 5+ years

A-Dec †
Jeromy Moss
(317) 517-2763 ph
jeromy.moss@a-dec.com

Brasseler USA †
Scott Kirk, Sue Denitoo
(912) 925-8525 ph
scottkirk@brasselerusa.com
suedenitoo@brasselerusa.com

All Dental Studios †
Steve Lewis, LeeAnn Lewis,
Cherrie Leonard, CDT
(317) 251-0200 ph
all1998@sbcglobal.net

Colgate Oral Pharmaceuticals
Michele Oddo
(630) 880-4616 ph
michele_oddo@colpal.com

Benco Dental Company †
Pamela J. Perkins,
Nathan Courney, Blake Ring
(800) 462-3626 ph
syearout@benco.com

Contour Specialists Dental Laboratory, Inc. ‡
Rick VanMeter, Martha Tritask
(317) 706-8500 ph
rick@contourspecialists.com

Crosstex Inc.
Gaylene Baker
(630) 738-8194 ph
gaylene@crosstex.com

Designs for Vision, Inc. †
Julie Harder
(800) 345-4009, ext. 311 ph
conventions@dvimail.com

GlaxoSmithKline Consumer Healthcare
Monica Bronowicki
(630) 927-8212 ph
monica.bronowicki@gsk.com

Henry Schein Dental
Scott Bauer, Erin Marcum
(317) 293-0111 ph
michael.kamp@henryschein.com
scott.bauer@henryschein.com

Hu-Friedy Mfg. Co., LLC
Jill Walker
(773) 575-5072
jwalker@hufriedy.com

IUSD Alumni Association ‡
Karen Jones
(317) 274-8959 ph
kdeery@iupui.edu

Indiana Dental Association
Jay T. Dziwlik
(317) 634-2610 ph
jay@indent.org

Johnson & Johnson
Wendy Swanson
(810) 397-3482 ph
WSwanso1@its.jnj.com

Kerr Dental Corporation
Todd O'Brien
(773) 307-0153 ph
Todd.obrien@sybrondental.com

Medical Protective ‡
Mary Taylor
(800) 463-3776 ph
Mary.Taylor@medpro.com

Midway Dental Supply, Inc. ‡
Bill Myers, Jim Crawford
Carling Cochran
(317) 295-9167 ph
bill@midwaydental.com

Orasoptic Research †
Michelle Ulrich
(586) 909-6440 ph
michelle.ulrich@sybron.com

Patterson Dental Supply, Inc. §
Robert Meeks, Pat Crowley
Ryan Greulich
(317) 733-4900 ph
patcrowley@pattersondental.com

Philips Sonicare
Janette Delinger, RDH, Erin Mulloy
(203) 351-5752 ph
Samantha.telegadis@philips.com

Procter & Gamble/Crest
Lenny Barnette
(847) 263-0288 ph
barnette.lh@pg.com

Q-Optics
Grover Knight
(800) 858-2121 or
(972) 298-2669 ph
support@q-optics.com

Shofu Dental Corporation
Bob Garnica
(800) 827-4638 ph
customer-service@shofu.com

Surgitel †
David Liszewski
(800) 959-0153 office ph
(734) 277-4127 cell ph
pennylee@surgitel.com
dliszewski@surgitel.com

Treloar & Heisel, Inc. †
Tim Turner, D.D.S., Shawn Johnson
(800) 345-6040 ph
info@th-online.net

Index to Primary Presenters and Mentors

Boldface names and numbers indicate primary presenters, posters (P) and clinical cases (CC).

- Abbott, L., CC6
Adair, A., P24
Ahdab, H., P67
Al Dehailan, L., P18
Allison, L., CC1
Alobaidi, E., CC31
Alshara, S., P1
Al-Shibani, N.K., P81
Alyas, S., P29
AlZain, A., P17
An, Y., P39
Ando, M., P10
Ariail, V., P70
Arthur, R.A., P11
Au-Yeung, J., P30, CC29
Beck, R., CC12
Bennett, S., P84
Bikorimana, E., P43
Blane, A., CC20
Bottino, M.C., P3, P20, P66,
P67, P68, P74, P75
Bruzzaniti, A., P12, P46, P78
Carlson, T., CC32
Chai, B., P55
Chaudhari, R., P44
Chin, J., CC28
Cho, S., P4, P28, CC1
Chong, V.J., P16
Christen, A., P83
Chu, T.G., P22, P30
Clark, P., P63
Coan, L.L., CC2, CC3, CC4
Cole, E., P26
Corcoran, J.G., P68
Couch, T., P63
Cruz Marroquin, E., P59,
CC27
Czarkowski, K., P64, CC32
Davenport, M., CC8
DelaCruz, K., P79
Deweese, F., CC5
Ehrlich, Y., P25, P76
Eleniste, P., P46
Ely, M., P13
Emhardt, J.R., P71
Escoffie-Ramirez, M., P48
Fahringer, K., CC19
Ferreira Zandoná, A., P6, P7
Flook, M., CC7
Foltz, J.A., P36
Gans, S., P58
Gardner, R., P37
Gebreslassie, S., P38
Ghoneima, A., P23, P47, P57
Gomez, G., P7
Gregory, R.L., P34, P35, P36,
P37, P38, P40, P41, P42,
P43, P44, P86, P88
Gregson, K.S., P19
Gupta, V., P42
Hansen, V., P52
Hara, A.T., P1
Heath, A.K., CC4
Heeke, K.S., P41
Howard, L., P15
Huang, R., P86
Huang, S., P12
Hungate, K., P54
Iannotti, J., CC14
Isyutina, O., P9
Jakubowicz, P., P28
Jenks, D., P76
Jeppson, J.K., CC25
Kamp, T., P74
Khaled, M., P32
Kimmel, T.J., P73
Kohara, E.K., P10
Kowolik, J.E., P64, P65
Kula, K., P47, P57
Labban, N., P5
Lambert, H.A., CC9
Landstoffer, A., CC3
Lanier, B., P34
Lecher, C., CC17
Levon, J., CC30, CC31
Liu, S., P59, P60, P61, P62
Loner, C., P45
Love, K., CC18
Ludwig, K., P65
Mandiwala, R., P85
Martinez-Mier, E.A., P8, P50,
P71
Matis, B.A., P2
Matis, J.I., P2
Maupomé, G., P9
McCrea, E., P53
Meadows, M.L., CC5, CC6,
CC7, CC8
Mogg, M., CC21
Moody, K., CC23
Nassar, H.M., P22
Neese, J.A., P72
Negrini, T., P33
Nishigori, A., CC30
Ombrembowski, M., CC15
Palasuk, J., P4
Pezeshk, M., CC28
Phillips, S., CC20, CC21, CC22,
CC23
Platt, J.A., P17, P18, P21, P27,
P51
Posritong, S., P20
Pradhan, M., P77
Prakasam, S., P69, CC29
Pycinska, K., P51
Rackley, R.H., CC17, CC18,
CC19
Ratliff, L., CC16
Rayls, E., CC11
Rettig, P., CC13, CC14, CC15,
CC16
Rexford, A., CC24
Rigsbee, O.H., CC27
Rodenbeck, J., P80
Romito, L.M., P31, P82, P84,
P85
Sabrah, A., P3
Sanders, B., P24
Scheer, B., P88
Shah, N., P78
Shamo, B., P89
Shango, J., P87
Shobe, A., CC2
Smith, M., CC13
So, K., P19
Soto-Rojas, A.E., P48, P50
Spolnik, K.J., CC24, CC25,
CC26
Srinivasan, M., P33, P69, P77
Starr, A.C., P66
Stewart, K.T., P13, P52, P53,
P54, P55, P56
Stump, N., CC12
Svetanoff, E.R., P31
Taing-Watson, E., P56
Tursunova, R., P35
Ward, D., P23
Werner, B., P14
Wetzel, H., CC10
Whatley, J.J., CC26
Willingham, C.B., CC22
Windsor, L.J., P5, P32, P79,
P80, P81
Wu, D., P60
Xia, Z., P62
Xie, D., P15, P16
Yassen, G., P75
Yoder, K., P72, P73
Yoshida, T., P27
Young, N.A., CC9, CC10, CC11

Johnson & Johnson

HEALTHCARE PRODUCTS

Division of McNEIL-PPC, Inc.

LISTERINE®

ANTISEPTIC

REACH®

Proceedings of

1st Annual Research Day

Indiana University School of Dentistry
Thursday, March 25, 1993
2:00-5:00pm
Conference Center, IUPUI



Indiana University School of Dentistry
Indiana Section of American Association for Dental Research

RESEARCH DAY

Proceedings of the Second Annual
University Place Conference Center
March 31, 1994



Presented by
Indiana University School of Dentistry
and
Indiana Section, American Association
for Dental Research

INDIANA UNIVERSITY

RESEARCH DAY

Proceedings of the Third Annual
March 27, 1995



Presented by
Indiana University School of Dentistry
and
Indiana Section, American Association for Dental Research

Research Day

Fourth Annual

Proceedings
April 8, 1995
University Place
Conference Center

Presented by
Indiana University
School of Dentistry
and
Indiana Section,
American Association
for Dental Research

INDIANA UNIVERSITY

researchday

Fifth Annual

Proceedings
March 31, 1997
University Place
Conference Center

Presented by
Indiana University
School of Dentistry
and
Indiana Section,
American Association
for Dental Research


RESEARCH DAY

Indiana University School of Dentistry



8th Annual Proceedings
University Place Conference Center
April 24, 2000

Research Day




Sixth Annual Proceedings

April 13, 1998
University Place
Conference Center

Presented by
Indiana University School of Dentistry
and
Indiana Section, American Association for Dental Research

RESEARCH DAY



7th Annual Proceedings
University Place Conference Center, April 5, 1999


Presented by Indiana University School of Dentistry and Indiana Section, American Association for Dental Research

Indiana University School of Dentistry

9th Annual Proceedings
University Place
Conference Center
April 13, 2001

Presented by
IUSD and Indiana Section,
American Association
for Dental Research

RESEARCH DAY



Indiana University School of Dentistry

10th Annual Proceedings
University Place
Conference Center
April 1, 2002

Research Day

Presented by IUSD
and Indiana Section,
American Association
for Dental Research




Research Day

Indiana University School of Dentistry
11th Annual Proceedings
April 22-23, 2003


Presented by IUSD and Indiana Section, American Association for Dental Research

Research Day 2004



12th Annual Proceedings
April 13-14

Presented by IUSD and Indiana Section, American Association for Dental Research



Indiana University School of Dentistry

13th Annual Proceedings
April 12-13, 2005

Presented by
IUSD and
Indiana Section,
American Association
for Dental Research

RESEARCH DAY